

Wednesday, March 19, 2003

WEDNESDAY
AFTERNOON

Mini-Oral Presentations Session I
Innovative Enabling Cardiac Techniques

Abstracts 1 - 9

(Brittany / Champagne Rooms)

ABSTRACT 1

FACILITATED APPROACH TO PROXIMAL VEIN ANASTOMOSES IN CORONARY SURGERY: ONE YEAR ANGIOGRAPHYC RESULTS

Roberto Scrofani, Guido Gelpi, Massimo Lemma, Carlo Antona.
Department of Cardiovascular Surgery, "Luigi Sacco" Hospital, Milan Italy

OBJECTIVE : To determine the feasible, effective and procedural risk factors in one-shot proximal anastomotic device in coronary surgery.

METHOD : Since november 2000 68 Simmetry Aortic Connector (St Jude Medical Inc) (SAC) were deployed in 59 patients (pts) undergoing coronary revascularization. Preoperative clinical risk-score was 5.82+3.32. Six pts (10.1%) were reoperation and 44 (74.6%) were off pump. Graft function was tested intraoperatively measuring blood flow by Doppler analysis; postoperatively and one year after surgery angiography was performed.

RESULTS : Deployed of the SAC,without aortic clamping,was instantaneous and no technical problems were detected in all pts.One (1.6%) pt died of myocardial infarction following acute trombooses of the SAC four days after surgery. Postoperative angiography was done in 54/58 pts (93.1%); 60/63 SAC (95.2%) were patent between these 2 pts (3.3%) revealed a subocclusion of the vein graft due to kinking. One year angiographic control in 10/56 pts (17.8%) showed a good patency rate in 90.9% of the SAC.

CONCLUSION : The SAC for saphenous vein graft anastomoses creates a safe reproducible results especially in off-pump procedure. The use of sutureless device reduces the technical demand and avoids aortic clamp. SAC should be very carefully positioned to avoid any graft kinking.

ABSTRACT 2

DO CARDIAC STABILIZERS REALLY STABILIZE THE ANASTOMOTIC SITE?

Mangini A., Lemma M., Redaelli A., Cattaneo E., Acocella F., Monaco A., Fumero R., Antona C.

Cardiovascular Surgery Dpt, L.Sacco Hospital, Milan

Bioengineering Dpt, Politecnico di Milano

Veterinary Medicine Dpt University of Milano

OBJECTIVE: Anastomotic site motility measurement during 'off pump' CABG.

METHODS: Three different stabilizers have been valued in 10 Italian landrace pigs. Reconstruction of the anastomotic site movements was done in the three-dimensional space after images obtained by 2 digital cameras acquisition and elaboration with an original algorithm. Continuous monitoring of BP, PAP, LAP, RAP has been assessed.

RESULTS: The 3-Dimensional Distance showed a significant movement reduction using stabilizers (LAD 5.32 ± 0.5 vs 1 ± 0.1 mm; $p < 0.0001$; LPD 4.16 ± 0.3 vs 0.8 ± 0.21 mm; $p < 0.0001$; MB 4.13 ± 0.3 vs 1 ± 0.25 ; $p = 0.0101$). The average motility reductions were 81.4%, 80.5%, 75.7. The stabilizer use showed a heart rate increase: (41% on LDP $p < 0.0001$ and MB $p < 0.0001$; 27% on LAD $p < 0.002$), a mean BP reduction (-35% on LDP $p < 0.0001$, -44% on MB $p < 0.0001$, -30% on LAD $p < 0.0001$); on LAD only an increase in mean LAP (+38%; $p = 0.046$) and an increase in RAP: 43% on LDP ($p = 0.037$), 52% on MB ($p = 0.006$).

CONCLUSION: Cardiac stabilizers can reduce but not cancel the anastomotic site motility in association with peculiar hemodynamic modifications related to the involved artery.

WEDNESDAY
AFTERNOON

ABSTRACT 3

ROBOTIC LIMA TO LAD ANASTOMOSIS DURING FULL STERNOTOMY ON PUMP MULTIVESSEL CABG: PRACTICAL SUPPLEMENTATION OR QUESTIONABLE DIVERSION?

Frank Isgro, Arndt-H. Kiessling, Markus Blome, Werner Saggau,
Heart Institute Ludwigshafen

INTRODUCTION: Technical and time related considerations during totally endoscopic coronary artery bypass (TECAB) are reported. We questioned whether it is possible to use the Zeus Microwrist in a safe and timely manner during routine CABG operations.

METHODS: We report about 36 patients (mean age 63.2 ± 4.6 years; 30 male; EF $53 \pm 8\%$) in which we used the Zeus with 3D visualization for the distal IMA-LAD anastomosis. The Zeus arms were mounted pre-operatively and remained sterile until deployment. We used a virtual alpha port as instrument holder in order to avoid insertion of trocars.

RESULTS: The duration of Zeus supported anastomosis (Prolene 7.0/8cm) reached a mean of 28 ± 8 minutes. In 7/36 patients the suturing was completed manually. In 5 cases correction stitches were necessary. IMA flow was adequate in all patients.

CONCLUSION: The Zeus telemanipulator facilitates the application of robotic technology not only in selected patients scheduled for TECAB operations, but also in patients with fully equipped onpump multivessel CABG. Adoption of this integrated concept can back up the learning curve and increase the acceptance of otherwise time-consuming complete robotic operations.

ABSTRACT 4

AGGRESSIVE INTRAOPERATIVE THERMOREGULATION IMPROVES OFF-PUMP CORONARY ARTERY BYPASS GRAFTING OUTCOMES.

Y. Joseph Woo, M.D., Albert T. Cheung, M.D., University of Pennsylvania

BACKGROUND: Unintentional systemic hypothermia is common during off-pump coronary artery bypass grafting (OPCAB) and results in peripheral vasoconstriction and elevation in systemic vascular resistance, cardiac afterload, and myocardial oxygen requirements as well as coagulopathy and increased postoperative bleeding and transfusion requirements. These issues may be magnified in robotically assisted cases where total operative times are prolonged. Raising ambient room temperature, and warming intravenous fluids and ventilator gases have limited effect. Warm air circulating blankets placed around the entire periphery of the patient are cumbersome and pose a theoretical risk of blowing non-sterile air around the operative field. Commercially-available, computer-controlled, water-circulating, dorsal surface, active warming systems were utilized during OPCAB and patient outcomes were evaluated.

METHODS: Fifty-two consecutive patients underwent OPCAB by a single surgeon, either with the described adjunctive warming system (thermoregulator group, n=27) or without (control group, n=25). Multiple perioperative parameters were retrospectively compared among the two groups and statistically analyzed.

RESULTS: See table below. Additional demographic parameters such as the incidence of various comorbidities were not statistically different between groups. Thermoregulated patients began OPCAB at the same core temperature as controls but maintained a more physiologic temperature intra- and postoperatively. Thermoregulated patients bled less postoperatively, required less transfusions, recovered more quickly and were discharged sooner. There were no reexplorations, major perioperative morbidities or mortalities in either group.

Parameter	Control	Thermoregulator	Pvalue
Age	63.5 ± 2.2yrs	63.9 ± 2.1yrs	NS
Ejection Fraction	48 ± 3%	52 ± 3%	NS
Number of Grafts	2.6 ± 0.2	2.9 ± 0.2	NS
Starting temp	35.8 ± 0.2°C	36.0 ± 0.1°C	NS

WEDNESDAY
AFTERNOON

Parameter	Control	Thermoregulator	Pvalue
Lowest intraop temp	35.0 ± 0.2	35.8 ± 0.1	0.002
Ending temp	35.6 ± 0.2	36.7 ± 0.1	0.00004
One hour postop temp	35.8 ± 0.2	36.8 ± 0.1	0.0006
24hour chest tube output	144 ± 153ml	769 ± 58ml	0.015
PRBC transfusion	2.7 ± 0.6U	1.3 ± 0.3U	0.027
Time to extubation	11.1 ± 2.0hr	7.2 ± 0.9hr	0.045
Length of Stay	5.2 ± 0.3days	4.1 ± 0.2days	0.002

CONCLUSIONS: Aggressive maintenance of a more physiologic temperature during OPCAB reduced postoperative bleeding, transfusion requirements, mechanical ventilation time, and length of stay. Although not directly investigated in this initial report, these results may be due in part to the improving cardiac afterload and blood component function. These effects may become even more pronounced in patients requiring extensive off-pump revascularization, reoperations, and robotically-assisted cases.

ABSTRACT 5

ALTERNATIVE REVASCULARIZATION STRATEGIES: CAREFUL PATIENT SELECTION WITH TMR YIELDS IMPROVED OUTCOMES

Masoud AlZeerah; MD, FRCSC, Northwest Texas Healthcare, Amarillo, Texas

BACKGROUND: Alternative myocardial revascularization techniques are providing various new options to maximize patient benefit beyond the traditional standards of CABG and PCI. Transmyocardial revascularization (TMR) has emerged as one of these options.

METHODS: 34 consecutive limited-option patients were carefully selected and underwent TMR via left lateral thoracotomy with a Holmium: YAG laser. Patients were followed for 12 months. Baseline characteristics included maximum doses of at least two anti-anginal medications and previous CABG and/or PTCA in all patients, >90% with triple-vessel disease, 85% with hypertension, 50% with diabetes, mean LV function of 47%, 95% in CCSAS Class III and 5% in Class IV. LVEF < 30% and CHF were exclusion criteria. An epidural catheter was used to reduce postoperative pain.

RESULTS: 91% of TMR-treated patients had 2-class angina reduction at 12 months. No patients were readmitted for cardiac complications. Average length of hospital stay was 4.5 days. Mortality was 3%.

CONCLUSION: Careful patient selection in this challenging cohort resulted in significant angina improvement and low mortality. 85% of TMR-treated patients were in CCSAS Class I, or lower, 12 months after TMR.

WEDNESDAY
AFTERNOON

ABSTRACT 6

A NEW APPROACH FOR ATRIAL SEPTAL DEFECT CLOSURE IN PEDIATRIC PATIENTS - LATERAL MINI-THORACOTOMY IN PEDIATRIC PATIENTS

Alexander Kadner, MD; Hitendu Dave, MD; Marko I Turina, MD;
René Prêtre, MD
Clinic for Cardiovascular Surgery, University Hospital Zurich, Zurich,
Switzerland

OBJECTIVES: Antero-lateral thoracotomy has been advocated as a cosmetically superior alternative to sternotomy for closure of atrial septal defects (ASD). However, the incision has led to several complications such as phrenic nerve palsy or subsequent breast and chest wall deformities. We report the initial results of using a lateral mini-thoracotomy at the mid-axillary line for repair of ASD in pediatric patients.

METHODS: 15 patients (male 6, female 9) with a median age of 5 years (range: 4-14) were operated on for ASD type II (n=14) and partial AV-canal (n=1) via a lateral mini-thoracotomy between 10/1999 and 3/2002. Two patients had a partial anomalous pulmonary venous return (APVR) and one patient a mitral cleft. Special features of the approach included a short incision, preservation of the parietal musculature, establishment of cardiopulmonary bypass (CPB) with a central (n=8) or peripheral (n=7) cannulation, and repairing of the defect under ventricular fibrillation (VF). TEE was available in all patients. The defect was closed primarily in all but the two patients with APVR (where a baffle patch was used); the mitral cleft was closed.

RESULTS: Median CPB-time was 45 min and VF-time 13 min. No intra- or post-operative complications occurred. TEE confirmed perioperatively the absence of residual defect. The length of the incision ranged between 4 to 6 cm; the incision is hidden by the arm in a resting position in all patients.

CONCLUSIONS: Lateral mini-thoracotomy can be safely performed to repair ASD with cosmetically superior results compared to median sternotomy and right anterior thoracotomy. This approach could be the best alternative to percutaneous closure of ASD.

ABSTRACT 7

EXTRAPLEURAL APPROACH FOR THE REPAIR OF AORTIC ISTHMUS STENOSIS IN INFANTS: A USEFUL TECHNIQUE.

Hitendu Dave 1, Alexander Kadner 1, Margrit Fasnacht 2, Marko Turina 1, Rene Pretre 1

1. Clinic for Cardiovascular Surgery, University Hospital Zurich.
2. Department of Cardiology, Childrens Hospital Zurich.

OBJECTIVE: To study the feasibility and usefulness of an extrapleural approach (EPA) for extended resection and end to end anastomosis of aortic isthmus stenosis (AIS) in infants.

MATERIALS and METHODS: 10 consecutive patients undergoing surgical repair for AIS using EPA from June - Dec 2002. The median age was 7 days and median weight 3210 grams (Range: 980 - 3570gms). The aorta was approached through a 4th space posterior minithoracotomy. The latissimusdorsi was split; not the serratus anterior. The parietal pleura was gently spread apart from the thoracic cage to expose the thoracic aorta. The isthmus resection was performed in a standard manner. Three patients underwent PA banding. Except in 2 patients with opening of the pericardium, the thorax was closed without drainage.

RESULTS : All patients survived the operation. Postop echocardiography showed no significant gradients across the neoisthmus. The ratio of descendens/ascendens flow velocity decreased from 2.2 to 1.45 (Median). The median cross clamp time was 25 min (25 ± 7) and the duration of operation was 90 min (101 ± 27).

CONCLUSIONS : EPA for surgical repair of AIS is feasible and safe and offers a comfortable exposure of the aorta. It minimizes lung trauma and keeps the pleural space free of adhesions. This may be helpful in patients requiring a subsequent sternotomy or thoracotomy.

WEDNESDAY
AFTERNOON

ABSTRACT 8

CONCOMITANT ANTI-ARRHYTHMIA SURGERY, USING IRRIGATED RADIOFREQUENCY ABLATION (SICTRA) IN CABG PATIENTS

K. Khargi, Th. Deneke, K-M. Mueller, B. Lemke, A. Laczkovics
Cardiothoracic Surgery, Cardiology, Pathology
University Hospital Bergmannsheil, Bochum, Germany

BACKGROUND: This prospective study evaluated a new indication for an additional anti-arrhythmic surgical procedure, in CABG patients with chronic atrial fibrillation.

METHODS: 32 CABG patients, with a mean (SD) age 67.9 yrs (8.0); left atrial diameter 46.4 mm (8.0), duration AF 78 months (79), LVEF 53 % (15), euroscore 5.6 (2.6), had a SICTRA procedure, which was performed with a hand-held cooled-tip ablation catheter: Only metoprolol (95 mg retard) was given postoperatively. Cardioversion was not performed before the 6th postoperative month.

RESULTS: The mean (SD) number of distal anastomosis was 3.3 (1.2), aortic cross-clamp time 92 minutes (18). Thirty-day mortality was 3.1 % (1/ 32). The mean (SD) follow up was 22.3 months (14.4). The cumulative survival rates at 12 and 24 months 95 % and 89 %. The cumulative postoperative SR rates at 3, 6 and 12 months are 54 %, 69 %, 76 %.

CONCLUSION: Chronic AF, in CABG patients, is an appropriate new indication for a concomitant SICTRA procedure.

ABSTRACT 9

ALLOGENEIC BLOOD TRANSFUSION REQUIREMENTS AFTER MINIMALLY INVASIVE VERSUS CONVENTIONAL AORTIC VALVE REPLACEMENT: A RISK-ADJUSTED ANALYSIS

Sotiris C. Stamou, MD, Ph.D; Emmanouil I. Kapetanakis, MD; Robert C. Lowery, MD; Arvind K. Jain, MS; Timothy L. Frankel, MS; Albert J. Pfister, MD; Mercedes K.C. Dullum, MD; Louis Kanda, MD; Paul J. Corso, MD.

1. Section of Cardiac Surgery, Georgetown University Hospital, Washington D.C.
2. Section of Cardiac Surgery, Washington Hospital Center, Washington, D.C.
3. Statistics and Computer Center, MedStar Research Institute, Washington, D.C.

BACKGROUND: Aortic valve replacement (AVR) through a partial sternotomy (mini-AVR) was associated with improved outcomes, when compared with conventional AVR. We sought to investigate whether mini-AVR may yield decreased transfusion requirements over conventional AVR.

METHODS: From January 1997 through December 2001, 559 patients underwent isolated AVR (mini-AVR, n=56 Vs. conventional AVR, n=503). A multivariate logistic regression analysis was used to adjust for potential imbalances between groups. Risk score of the Parsonnet's risk stratification model was included as a covariate.

RESULTS: No patient in the mini-AVR group required conversion to sternotomy. Cardiopulmonary bypass time was longer in the mini-AVR than in the conventional AVR group [103 (50-367) Vs. 76 (45-442) min, $p < 0.01$]. A total of 31 patients (55.4%) in the mini-AVR and 377 patients (75.0%) in the conventional AVR group were transfused throughout their hospital stay ($p < 0.01$). After adjusting for Parsonnet's scores the difference was not statistically significant (Odds ratio=0.65, 95% Confidence intervals = 0.35-1.21, $p=0.18$).

CONCLUSION: Mini-AVR may produce better wound cosmesis and less surgical trauma but requires prolonged cardiopulmonary bypass time to perform. Risk-adjusted analysis failed to demonstrate a significant difference in blood transfusion requirements after mini vs. conventional AVR approach.

WEDNESDAY
AFTERNOON

Wednesday, March 19, 2003

Fireside Chat Clinical Rounds I

(4 Parallel Sessions)

Session A

Anastomotic Complications

Abstracts 10 - 15

(Le Mans Room)

Session B

Interoperative Management and Anticoagulation

Abstracts 16 - 21

(Bordeaux Room)

Session C

Sternal Wound Complications and Strokes

Abstracts 124, 23 - 26, 111

(Burgundy Room)

Session D

Potpourri of Videos

Abstracts 27 - 33

(Monaco Room)

WEDNESDAY
AFTERNOON

ABSTRACT 10

THIS IS A REPORT OF A LETHAL COMPLICATION FOLLOWING APPLICATION OF THE ST. JUDE AORTIC CONNECTOR.

Rick V. Bernstein, MD; Mercy Hospital, Scranton, PA, USA

A 57-year-old male underwent urgent OPCAB operation for peri-infarction angina due to multi-vessel in-stent restenoses. The proximal graft to the aorta for the RCA bypass was done using a St. Jude Symmetry device without incident. Satisfactory graft flows were measured with low PI's (pulsatility index)

On the morning following surgery, the patient suffered a sudden cardiopulmonary arrest after a few seconds of severe bradycardia progressed to ventricular fibrillation. The patient was returned to the operating room. The sternal incision reopened, and the proximal part of the aorta was covered with a hematoma containing an ongoing oozing site. Removal of this hematoma revealed the aortotomy for the RCA graft intact but freely bleeding.

The symmetry device connector with the attached proximal end of the right coronary vein graft was found within the hematoma approximately 2 centimeters from its aortotomy. Although satisfactory regrafting was done, and the patient separated from bypass with use of an intra-aortic balloon assist, the patient had shown no signs of awakening and developed severe hypoxic encephalopathy, and subsequent death.

Until the mechanism(s) of these device failures are determined and preventative measures developed, we would urge caution in the use of these devices.

ABSTRACT 11

COMPLICATION OF SUCTIONS STABILIZING DEVICES DURING OFF PUMP CORONARY ARTERY SURGERY

Dr. Nitu Mandke, Dr. Ajay Choughule, Dr. Shirish Borker, Dr. Zubin Nalladaru, Dr. Alka N. Mandke.
Lilavati Hospital and Research Centre, Mumbai, India.

AIM: To understand the hazardous effects of suction pads on the epicardium and myocardium and to take preventive actions.

MATERIAL & METHODS: Cardiac stabilizers with suction pads became available to us by January 2002. The use of this stabilizer allowed the exponential growth in the number of offpump surgeries all over the world, as the coronary arteries on the back of the heart became accessible for grafting. From 1st January 2000 till 30th June 2002, 1377 patients underwent offpump coronary artery surgeries. Two of these 1377 patients developed complication directly related to the suction device. Epicardium got separated from the myocardium avulsing the intramyocardial blood vessels underneath the imprint of suction pads producing haematoma, which progressed undermining epicardium over a large portion of heart and produced burrowing of haematoma into the myocardium. It gave the appearance of ruptured heart with torrential bleeding. Both these patients were treated by going on C P Bypass by evacuating haematoma and obliterating the cavity with biological glue.

RESULTS: One patient died 2 hrs postoperatively due to uncontrolled bleeding. The next patient survived the operation and was discharged home on 12th P.O. day.

CONCLUSION: Any expansion of suction pad mark should be immediately treated and it should not be allowed to progress and expand and burrow within the myocardium. This complication can occur at low or normal level of suction pressure and may be attributed to the weakness between the epicardium and myocardial fibrils.

WEDNESDAY
AFTERNOON

ABSTRACT 12

ACUTE AORTIC DISSECTION OR GRAFT CLOSURE - AND NOT PULMONARY EMBOLISM - ARE THE LEADING CAUSES OF SUDDEN DEATH AFTER CABG

Imad Tabry, MD; Holy Cross Hospital, Fort Lauderdale, FL, USA

BACKGROUND: Acute aortic dissection (AOD) can occur intraoperatively or late, up to several years after cardiac surgery. Its recognition and management are well documented. Recent reports indicate it may also occur very early, within a few days of an otherwise uneventful operation. Its recognition then is more difficult, and its lack of may result in sudden unexplained death, previously attributed to "massive PE". Similarly sudden death may occur after acute graft occlusion, particularly after OPCAB, and earlier reports have prompted systematic prophylactic anticoagulation to prevent this catastrophic event.

METHODS AND RESULTS: In our Institution (650 cardiac operations/year), postoperative sudden unexpected hemodynamic collapse (POSHC) has occurred on an average 2 to 3 times each year, during hospitalization or early after discharge, in CABG patients (both OPCAB and ONCAB), usually resulting in death from "massive PE" without autopsy confirmation. In the past year, 2 patients ready for discharge and 1 already discharged sustained POSHC. 2 had early acute AOD originating at the proximal anastomosis (1 conventional and 1 using a mechanical connector on an atheromatous aorta). Initial presentation was lower extremities paresis 5 days post OPCAB in a 75 year old male, and CHF with new AI murmur in an 89 year old female a week after discharge and ONCAB. Diagnosis was confirmed by TEE and CT. The first underwent successful repair while the second refused surgery and died. The 3rd patient complained of severe shoulder pain, then went into POSHC 5 days after uneventful OPCAB. After open chest resuscitation she was found to have an occluded vein graft to a dominant RCA and survived surgery.

CONCLUSION: In the past, sudden unexpected POHC after uneventful OPCAB or ONCAB was attributed to PE. Closer review indicates it is more commonly the result of acute graft closure or early AOD. Both entities are difficult to recognize early and require a high index of suspicion as any delay in surgical treatment is associated with a definite risk of death from massive infarction and cardiogenic shock in the former, or rupture and tamponade in the latter. Expeditious bedside resuscitation and return to the OR, or TEE and CT when possible, allow successful management of these dreadful and probably not so infrequent complications of CABG. Though recently reported in the

literature, the role of proximal mechanical connectors in initiating early postoperative graft closure or AOD remains unclear and will require prospective studies.

WEDNESDAY
AFTERNOON

ABSTRACT 13

EARLY GRAFT OCCLUSION IN CABG ASSOCIATED WITH NITNOL PROXIMAL CONNECTORS

Baron L. Hamman; Baylor University Medical Center at Dallas, Dallas, TX, USA

At BUMC, we have implanted many proximal connectors with success. With two however, we have documented early proximal graft occlusion. In one patient antibodies to heparin were noted and continued to circulate at the time of surgery; hirudin was used as the anticoagulant. In the second case a thoracic approach was used to create one vein graft to the obtuse marginal. In both patients "full anticoagulation" was accomplished during the CABG. Plavix was not used in either patient in the perioperative period. Both occlusions occurred after post operative day 3. I consider use of plavix to be critical in patients who have this device implanted because of the amount of exposed nitinol.

ABSTRACT 14

PERIOPERATIVE ISCHAEMIA AFTER CORONARY REVASCULARISATION: VALUE OF EARLY INTERVENTIONS

Kowalik V., Knapik P., Gašior M., Nadziakiewicz P., Przybylski R., Kalarus Z., Zembala M.

Silesian Centre for Heart Disease, Zabrze, Poland.

AIM: To assess the value of early interventions for perioperative ischaemia (PI) in patients (pts) after coronary revascularisation (CR).

MATERIAL AND METHOD: Among 2826 consecutive pts underwent CR, 70 pts (2.5%) due to PI required early intervention (up to 24 hours), 48 pts (1.7%) - acute angiography and 22 pts (0.8%), because of haemodynamic instability, immediately reoperation.

RESULTS:

	Early angiography n=48 pts			Peroperative n=22 pts	P
	all n=48	normal n=11	abnormal n=37		
	- graft occlusion -17 - graft stenosis - 6 - graft spasm -2 - TIMI I - 6 - poor distal run-off - 3	TIMI III	PCI-22 (45.8%) reoperation- 12 (25%)		
MI	37 (77.1%)	6 (54%)	31 (83%)	16 (72.7%)	0.88
Death	7 (14.6%)	1 (9.1%)	6 (16.2%)	14 (63.6%)	0.004

CONCLUSION: Early angiography in PI after CR is a safe and effective procedure. Pts with acute PI after CR may develop myocardial infarction despite normal angiographic findings. Mortality among those pts with PI who have to be immediately reoperated is significantly higher compare to pts with stable PI.

WEDNESDAY
AFTERNOON

ABSTRACT 15

ACUTE CORONARY ANGIOGRAPHY AFTER CABG: NECESSITY AND CONSEQUENCES

M. Eller, G. Tagarakis, H. Sahre, B. Boden, C. Georgi, V. Gulielmos
Heart Center Dresden University Hospital, Dept. of Cardiac Surgery;
Dresden, Germany

INTRODUCTION: Current standard of quality assessment of CABG is coronary angiography, but often the question arises when to perform angiography and with what consequences.

MATERIAL AND METHODS: We retrospectively analyzed 43 patients receiving acute coronary angiography from 01/2001 to 08/2002 after CABG. Seventeen patients (group 1) had CKMB/CK higher than 10%, 9 patients (group 2) received angiography due to new ischemia signs on ECG, 15 patients (group 3) due to both, and 2 patients (group 4) due to ventricular fibrillation.

RESULTS: In group 1 fourteen patients (88 %), in group 2 seven patients (78 %) and in group 3 fourteen patients (88 %) had anastomotic problems. In group 4 angiography revealed good patent grafts. Ten patients received subsequently additional operation and 2 patients (20%) died being already in cardiogenic shock. Nine patients received acute PTCA and/or stenting and 1 patient (11%) died. The remaining 16 patients with anastomotic complications underwent conservative therapy and 1 patient (6.3%) died.

CONCLUSIONS: Equal sensitive criteria for detection of anastomotic failures after CABG are the combination of increase of cardiac enzymes plus ECG ischemia signs or isolated increased cardiac enzymes. Reoperation during acute stadium offers best outcome unless patients are in cardiogenic shock.

ABSTRACT 16

STANDARD FORMULAS OVERESTIMATE PROTAMINE REQUIREMENTS IN OFF-PUMP CORONARY ARTERY BYPASS GRAFTING

Y. Joseph Woo, M.D., Timothy J. Gardner, M.D., University of Pennsylvania

BACKGROUND: Over the past eight years, approximately 8,000 cardiac surgical patients were operated upon at our institution and underwent activated clotting time (ACT) monitored heparin anticoagulation for cardiopulmonary bypass and protamine administration based upon a standard formula that has not changed during this period. This formula reflects the physiologic effects of bypass pump-induced dilutional coagulopathy, platelet dysfunction, and coagulation/fibrinolytic cascade component activation, factors not necessarily pertinent in off-pump coronary artery bypass grafting (OPCAB). This study sought to evaluate a strategy of decreased protamine dosing in OPCAB.

METHODS: Forty-seven consecutive patients underwent primary OPCAB by a single surgeon with full heparinization calculated for a goal ACT of 400 sec. A mean of 2.83 ± 0.14 grafts/patient were performed. For heparin reversal, protamine dosing was calculated by the standard institutional formula, 50% of this dose was administered, and the ACT was measured.

RESULTS: The mean baseline ACT was 137 ± 5 sec. After heparin administration, the mean ACT was 452 ± 12 sec. Just prior to protamine dosing, the mean ACT was 390 ± 10 sec. After protamine administration, the mean ACT was 123 ± 2 sec. Normalization of ACT to baseline levels was achieved with 50% protamine dosing in 43 of 47 patients, four patients required an additional 25% dose. All patients demonstrated intraoperative clinical evidence of hemostasis. Mean partial thromboplastin time (PTT) upon arrival in the intensive care unit was 39.5 ± 2.3 sec, statistically equivalent to a preoperative mean PTT of 34.8 ± 3.6 sec. ($p=0.26$). Mean 8-hour chest tube output was 412 ± 29 ml and mean 24-hour output was 807 ± 39 ml although this later value tends to reflect predominantly serous drainage from the left internal thoracic artery harvest bed. Mean PRBC transfusion was 1.5 ± 0.3 units/patient. There were no transfusions of platelets, fresh frozen plasma, or cryoprecipitate, no re-explorations, and no mortalities. Patients were discharged a mean 4.5 ± 0.2 days postoperatively.

CONCLUSIONS: A standard protamine dosing formula adequate for on-pump cardiac surgical procedures significantly overestimates protamine requirements for OPCAB. Decreasing protamine administration does not appear to adversely affect patient outcome.

WEDNESDAY
AFTERNOON

ABSTRACT 17

CARDIOPULMONARY BYPASS UNDER RECOMBINANT HIRUDIN: SAFE AND EFFECTIVE IN A PATIENT WITH TERMINAL KIDNEY DYSFUNCTION

Friedrich-Christian Riess, Nisa Awwad, Bettina Hoffmann, Wulf Neckel, Micheal Trinkwitz, Niels Bleese, Albertinen Hospital, Hamburg, Germany

OBJECTIVE: The isolated thrombin inhibitor recombinant (r-) hirudin has been used successfully in patients with heparin-induced thrombocytopenia (HIT) type II during cardiopulmonary bypass (CPB). Terminal kidney dysfunction is regarded as contra-indication for the use of recombinant hirudin because r-hirudin is mainly eliminated via the kidneys and no antidot is available.

MATERIAL AND METHODS: We report on a 67 year old woman (46 kg) with cardiac decompensation due to severe aortic, mitral, and tricuspid valve regurgitation besides chronic atrial fibrillation. After diagnostic heart catheterization the patient had developed anuria requiring daily hemodialysis. Furthermore she developed a HIT with positive HIPA-test and ELISA. Standard CPB was performed using r-hirudin anticoagulation (Refludan, Pharmion Ltd, Cambridge, England). After an initial bolus of 12.5 mg to the patient and another bolus of 10 mg into the priming of the CPB r-hirudin plasma levels were kept higher than 2.5 µg/ml by additional 5 mg boluses. Anticoagulatory monitoring during CPB was performed using the ecarin clotting time (ECT) assessed every 15 min.

RESULTS: Mechanical prostheses (aortic 23mm, mitral 29mm) were implanted and tricuspid annuloplasty (32mm) were performed without intra- and postoperative complication. During CPB the ECT was measured between 38 and 51 seconds corresponding to r-hirudin plasma levels between 3 and 5 µg/ml. The total amount of r-hirudin used during CPB was 57.5 mg. Towards the end of CPB a period of 69 min hemofiltration with a rate of 166 ml/min (total amount added volume 11,5 L) was carried out. A total amount of 9.43 mg r-hirudin was eliminated by hemofiltration.

CONCLUSION: Recombinant hirudin was used safely and effectively during CPB in a patient with HIT and terminal kidney dysfunction.

ABSTRACT 18

FIRST PROSPECTIVE STUDY OF FIBRINOGEN AND LIPID LOWERING BY HELP (HEPARIN-MEDIATED EXTRACORPOREAL LDL-/FIBRINOGEN PRECIPITATION) - APHERESIS TO PREVENT EARLY GRAFT OCCLUSION AFTER CABG.

Martin Oberhoffer, Department of Cardiac Surgery, University Hospital Grosshaden, Munich, Germany

BACKGROUND: Early graft occlusion due to thromboembolism occurs in up to 12% after CABG (Coronary Artery Bypass Grafting). Postoperatively highly elevated plasma fibrinogen levels, graft endothelial damage and the resulting activation of the coagulation cascade favor a prothrombotic response. In a prospective study we sought to determine whether postoperative lowering of fibrinogen and lipids by HELP (Heparin-mediated Extracorporeal LDL-/Fibrinogen Precipitation) - apheresis prevents early graft vessel occlusion in hyperlipidemic patients undergoing CABG.

METHODS: Between 12/2000 and 10/2002 fifteen hyperlipidemic male patients, mean age 60 ± 2 years, underwent CABG. Mean preoperative levels were for: Fibrinogen = 365 ± 12 , LDL-Cholesterol = 117 ± 16 Lpa = 39 ± 12 , Triglycerids = 402 ± 152 mg/dl. Postoperatively HELP-apheresis was employed when fibrinogen values exceeded 350mg/dl on day 1 and 250mg/dl every consecutive day up to day 8. Pre- and post-apheresis blood samples were obtained and reduction of plasma fibrinogen, LDL-cholesterol, Lpa and triglycerids was calculated. Coronary angiography was performed within 9-16 days.

RESULTS: 55 bypass grafts (27 arterial, 28 vein grafts) were performed in 15 patients (3.7 grafts/patient). Postoperatively 83 HELP-apheresis were applied (mean 5.5/patient) from day 1-8. Fibrinogen levels were lowered from 360 ± 12 mg/dl (pre-apheresis) to 157 ± 46 mg/dl (post-apheresis) ($p < 0.01$), LDL-cholesterol from 48 ± 12 to 23 ± 1 ($p < 0.01$), Lpa from 16 ± 2 to 8 ± 1 ($p < 0.01$), triglycerids from 155 ± 8 to 99 ± 5 mg/dl ($p < 0.01$). Coronary angiography revealed graft patency in 54 of 55 grafts (98% patency) with one closed Y-graft to a diagonal branch of 1mm in diameter. No HELP-related complications were observed.

CONCLUSIONS: Early and drastic postoperative reduction of Fibrinogen-, LDL-Cholesterol-, Triglycerid- and LpA-levels by HELP-apheresis offers a safe and promising tool in the prevention of early graft occlusion in hyperlipidemic patients undergoing CABG. To evaluate superiority of HELP- to non-HELP-apheresis treated patients further investigation concerning longterm graft patency is ongoing.

WEDNESDAY
AFTERNOON

ABSTRACT 19

COMPOSITE ARTERIAL GRAFTING: INFLUENCE AND COMPETITIVE FLOW ON GRAFT PATENCY

Pevni D, Herz I, Kramer A, Paz Y, Uretzky G, Mohr R.
Department of Cardiothoracic Surgery, Sourasky Medical Center,
Tel Aviv, Israel

BACKGROUND: Composite arterial grafting cause splitting of internal mammary artery flow to various myocardial regions. The amount of flow supplying each region depends on severity of coronary arteries steosis.

METHODS AND RESULTS: We show postoperative coronary angiograms demonstrating the influence of competitive flow on graft patency. The first patient had left internal thoracic artery (ITA) to LAD and radial artery (RA) to marginal and posterior descending artery (PDA). PDA stenosis was 70%. An angiogram with normal injection demonstrated absence of RA segment between marginal and PDA. Forced injection via ITA demonstrated this segment. The second and third angiograms demonstrated closure of segment of left ITA. Revascularization was performed for 70% LAD stenosis in the second case and 60% left main in the third case. In both cases, thallium SPECT showed normal perfusion of the anterior wall.

CONCLUSION: These findings suggest that composite grafting should be reserved for coronary vessels with severe and critical stenosis.

ABSTRACT 20

OFF-PUMP CORONARY ARTERY BYPASS GRAFTING ATTENUATES POSTOPERATIVE BLEEDING ASSOCIATED WITH PREOPERATIVE ASPIRIN AND CLOPIDOGREL ADMINISTRATION.

Y. Joseph Woo, M.D., Nicholas Valettas, M.D., University of Pennsylvania

OBJECTIVE: Clopidogrel and aspirin are commonly administered prior to cardiac catheterization in preparation for possible coronary stent implantation but surgical anatomy is often discovered. Recent findings indicate that patients surgically revascularized within seven days of clopidogrel exposure have markedly increased postoperative bleeding, transfusion requirements, and a ten-fold risk of reexploration and thus suggest delay of surgery, platelet administration, and elimination of the routine practice of pre-angiography clopidogrel administration. (1) This study sought to evaluate the potential role of off pump coronary artery bypass grafting (OPCAB) in eliminating the need to delay surgery and in decreasing postoperative bleeding.

METHODS: A retrospective review was conducted of ten patients who received clopidogrel in combination with aspirin prior to cardiac catheterization in anticipation of coronary stent implantation, were found to have surgical anatomy, and then underwent OPCAB without delay by a single surgeon. Eight and twenty-four hour chest tube outputs, transfusion requirements, and postoperative length of stay (LOS) \leq 5 days were analyzed and compared to a published group of 51 patients serving as a historical control.(1)

RESULTS: Postoperative chest tube outputs, blood product transfusions, and length of stay are detailed below. Among the ten OPCAB patients, there were no mortalities, reexplorations, myocardial infarctions, strokes, respiratory complications or sternal wound infections.

Parameter	Historical Control	OPCAB
N	51	10
8 hr Chest Tube Output (ml)	817 \pm 761	343 \pm 50
24 hr Chest Tube Output (ml)	1274 \pm 1165	814 \pm 77
PRBC (units)	2.6 \pm 2.5	1.1 \pm 0.3
Platelets (units)	0.9 \pm 1.3	0
FFP (units)	0.8 \pm 1.8	0
Cryoprecipitate (units)	0.2 \pm 1.4	0
LOS \leq 5 days (% patients)	34%	80%

WEDNESDAY
AFTERNOON

CONCLUSIONS: Among these ten OPCAB patients with immediate preoperative administration of clopidogrel and aspirin, postoperative bleeding, transfusion requirements and length of stay were less than historical controls. Recommended approaches to preoperative clopidogrel administration such as delay of surgery and platelet transfusion were not necessary in this group. The current practice of pre-angiography clopidogrel administration would not seem to require modification.

1. Hongo RH, Ley J, Dick SE, Yee R. The effect of clopidogrel in combination with aspirin when given before coronary artery bypass grafting. *J Am Coll Cardiol* 2002;40:231-7.

ABSTRACT 21

NEW APPROACH TO ANESTHESIA IN CARDIAC SURGERY FOR HIGH-RISK PATIENTS

S. Casalino, F. Mangia, L. Biancardi, C. Alessi, A. Benedetti, F. Guerra

AIM: The benefits ascribed to the employment of high thoracic epidural anesthesia (HTEA) include faster extubation, better control of postoperative pain and fast recovery of the respiration function.

MATERIALS AND METHODS: We enlisted 50 patients who had undergone CABG in 2 groups of 25 patients. Each group received intravenous anesthesia (TIVA: remifentanyl 0.2- 0.3 microgr/kg/min and propofol 3-5 mg/kg/h). Group B received blended anesthesia (HTEA T1-T2: bupivacaine 250mg and alfentanil 1 mg and propofol 3-5 mg/kg/h). Postoperatively, group A received morphine 0.07mg/kg every 6 hours; group B: bupivacaine 0.07mg/kg/h and alfentanil 4 microgr./kg/h in the peridural catheter. Postoperatively, we estimated the length of intubation, FEV1 and VAS at 24 and 72 hours.

RESULTS: The 2 groups were homogeneous in age, time of extracorporeal circulation and time of aortic clamping. At 24 hours FEV1 reduced to 32.2% in Group A and to 38% in Group B (p=0.14) vs the preoperative values. VAS was 5.4 (range 0-10) in Group A and 5.2 in Group B (p=0.2). At 72 hours FEV1 reduced to 44.4% in Group A and to 54% in Group B (p=0.07). VAS was 3.1 in Group A and 2.9 in Group B. Length of intubation: Group A 125 ± 45 min. and Group B 110 ± 80 min. (p=0.18).

CONCLUSION: Although this study did not show a real advantage of HTEA vs TIVA in this group of unselected patients, we think that larger dosage of anesthetic provides more effective control of postoperative pain, and the application of HTEA in patients with compromised respiratory function underscores the real advantages of this method versus TIVA.

WEDNESDAY
AFTERNOON

ABSTRACT 124

PRIMARY STERNAL PLATING IN HIGH-RISK PATIENTS AS PROPHYLAXIS AGAINST MEDIASTITIS

David H. Song, MD

University of Chicago Hospitals, Chicago, IL, USA

BACKGROUND: Sternal instability predisposes to post-sternotomy mediastinitis (PSM). Sternal osteotomies are predominantly closed with wire. Rigid plate fixation has been used successfully to increase stability and prevent infection following osteotomies for other bones. Therefore, we studied the utility of this technique for sternotomies in high-risk patients.

METHODS: High-risk patients were identified as having >3 recognized risk factors for PSM. Between July 2000 and December 2001, 45 patients (Group 1) had prophylactic rigid plate fixation, compared to a matched cohort of controls (Group 2) with similar risk factors that underwent conventional sternal wire closure (n=207).

RESULTS: Mean follow-up was 15 weeks (range 8 to 41 weeks). There were 4 peri-operative (8.8%) deaths in Group 1 and 18 in Group 2 (8.6%), unrelated to sternal complications. Incidence of PSM in Group 1 was 0, compared to 14.8% (n=28), in Group 2 (p=0.006). Total institutional incidence of PSM during the study period was 4.2%.

CONCLUSIONS: Mediastinitis increases morbidity, mortality and hospital stay after open-heart surgery. Primary sternal plating is an effective way of ensuring sternal immobility thereby reducing the substrate for bony infections. Application of this technique may act as prophylaxis against mediastinitis and promote early mobilization and recovery in high-risk patients.

ABSTRACT 23

TREATMENT OF STERNAL WOUND COMPLICATIONS WITH THE VACUUM-ASSISTED CLOSURE DEVICE

Claudio Muneretto, Gianluigi Bisleri, Jacopo Manfredi, Alberto Negri
Division of Cardiac Surgery, University of Brescia Medical School,
Brescia, Italy

We evaluated the effectiveness of the Vacuum Assist Closure (VAC) device in the treatment of sternal wound complications.

The VAC device consists of a sterile polyurethane foam dressing with an open-pore structure that can be trimmed in different shapes in order to fit the sternal wound. The wound is sealed with adhesive drape and a continuous negative pressure is applied. We used the VAC device was used in 16 patients (mean age: 75 ± 7 years) with sternal wound complications: positive cultures were found in 13 patients (*S. aureus*: 10 pts.; *Enterobacter*: 4 pts.). We observed a particularly high prevalence of diabetes (62.5%) and COPD (75%). Dressings were changed out every 48 hours.

We did not observe any extension of infection to deeper layers. Wound healing was achieved in all patients after a mean period of 18 ± 3 days despite an initial consistent lacking volume of tissue (mean 70 mL). Antibiotic therapy was administered for 10 ± 2 days.

The VAC device provided excellent results in the treatment of sternal wound complications stimulating granulation tissue ingrowth and promoting tissue approximation.

WEDNESDAY
AFTERNOON

ABSTRACT 24

A NOVEL TECHNIQUE FOR THE TREATMENT OF STERNAL WOUND INFECTION USING APPLICATION OF MACROPHAGES

Erez Kachel, Tel Aviv, Israel; Sheba Medical Center

BACKGROUND: Sternal wound infection remains a significant complication after open heart surgery. Reported mortality is up to 40%, time of hospitalisation may reach months and the average cost of hospitalization is three times higher than that of patients with an uncomplicated postoperative course. The heart - lung machine reduces the number and function of the macrophages by 70%. By using this technique, we aim to overcome this reduction. We describe here the practical aspects of managing post sternotomy wound infection using this approach.

METHODS: After developing a method for preparation of human macrophages suspension from a blood unit in a closed sterile system, the cells were activated by a hypoosmotic shock and injected into the infected open sternal wound incision.

65 patients were treated.

Group 1 - 28 superficial sternal wound infection

Group 2 - 29 deep sternal wound infection

Group 3 - 8 patients post failed sternal reconstruction surgery

RESULTS: Complete wound closure was achieved in 61 patients at 10 to 138 days (mean 46). In two patients a marked improvement was achieved and finally a simple direct closure was needed. Two patients died during the follow up.

CONCLUSION: In the appropriate patients, treatment with macrophages may reduce morbidity, lower mortality, prevent reoperation, and reduce the average postoperative hospitalization period and costs.

ABSTRACT 25

**A NEW METHOD FOR DELAYED STERNOTOMY HEALING :
THE VACUUM THERAPY**

Roland Demaria, Uberto Giovannini, Luc Téot, Jean-Marc Frapier,
Bernard Albat

Department of Cardiovascular Surgery and Department of Burns and Plastic
Surgery, Arnaud de Villeneuve Hospital, Montpellier, France.

PURPOSE: The purpose of this investigation was to apply the vacuum therapy
in cardiac surgery in order to achieve healing of delayed sternotomy closure.

MATERIAL AND METHODS: A total of 7 patients operated for coronary
bypass surgery by median sternotomies presented a non healing sternum surgical
wound treated by vacuum therapy. Aspiration maintained between -125 and -200
mmHg was done on the surface of the wound using a sponge connected
hermetically to an aspiration system. The treatment was associated with an
antibiotherapy adapted to the bacteriological results.

RESULTS: All patients with delayed sternotomy closure healed in about 8
weeks (2 to 12 weeks) but one who died of multiorgan failure. The treatment
was possible by vacuum therapy alone (n=2) or associated in second intention
with a skin graft (n=1) or both with a muscular pectoral flap (n=4).

CONCLUSIONS: This new therapy offers an alternative to classic treatment of
infected sternotomies in cardiac surgery, especially to prepare rewiring and
muscular flaps.

WEDNESDAY
AFTERNOON

ABSTRACT 26

CEREBRAL PROTECTION IN MINIMALLY INVASIVE HEART VALVE SURGERY: EVALUATION OF CARBON DIOXIDE INSUFFLATION IN A PORCINE MODEL

S.Martens, A.Theissen,* J.Balzer,** M.Dietrich, K.Graubitz, M.Doss, A.Moritz. Department of Thoracic and Cardiovascular Surgery, *Central Research Facilities, **Department of Diagnostic and Interventional Radiology, J.W.Goethe University Hospital, Frankfurt, Germany

BACKGROUND: Major risk of central or peripheral organ damage is attributed to air embolism from incompletely deaired cardiac chambers after minimally invasive heart valve operations. Replacement of air by carbon dioxide insufflation into the thoracic cavity is widely used. Diffusion weighted magnetic resonance imaging (DWI) was utilized to visualize reversibility of ischemia after gas embolization in a porcine model.

METHODS: After selective catheterisation of a common carotid artery in 15 pigs, boli of 1ml/kgBW of air (group I, n=5) or carbon dioxide (group II, n=5) were applied. Group III (n=5) received 2ml/kgBW of carbon dioxide. Diffusion weighted MRI (DWI) of the brain was performed 2, 5, 10, 15 and 25 minutes after embolization.

RESULTS: In group I, DWI revealed irreversible hyperintense signals in both hemi-spheres. In group II, no change in signal intensity was observed in two pigs, three others showed reversible changes in signal intensity, without important circulatory reactions. In three animals of group III, hyperintense signals were reversible, but two others presented with bilateral, irreversible signals in DWI.

CONCLUSION: Early reversibility of ischemic lesions visualized in DWI encourage the use of carbon dioxide insufflation to the operative field as a protective method in minimally invasive heart valve surgery.

ABSTRACT 111

AORTIC LEAFLET REPLACEMENT WITH THE NEW 3F STENTLESS AORTIC BIOPROSTHESIS. CLINICAL EVALUATION OF HEMODYNAMIC PERFORMANCE AND CORONARY FLOW

Mirko Doss;

Frankfurt am Main, Hessen, Germany

BACKGROUND: The 3F aortic bioprosthesis is a stentless biological heart valve fabricated from three equal leaflets of equine pericardium, assembled in a tubular shape, and implanted in the native aortic root, to replace the patient's diseased aortic leaflets. Clinical trials began October 2001 and being one of the first centres to implant this prosthesis in humans, we would like to present our experiences with this new device.

METHODS: Between January 2002 and August 2002, 24 3F aortic bioprosthesis were implanted at our institution. Effective orifice area, mean gradients and ejection fraction were evaluated echocardiographically at discharge and 6 months after surgery. Furthermore coronary flow before and after the implantation of the device were assessed via MRI-angiography.

RESULTS: At 6 months of follow-up the 3F bioprosthesis showed a good hemodynamic performance with a significant drop of mean gradients to 15.9 mmHg, a mean effective orifice area of 1.7 cm² and a mean ejection fraction of 61.5%. Coronary flow had significantly improved compared to preoperative values and reversal of preoperative systolic flow was abolished.

CONCLUSION: The clinical performance of the new 3F aortic bioprosthesis is comparable to regular stentless aortic valves. Its unique design features make it easier and quicker to implant than conventional stentless valves additionally an excellent restoration of coronary flow is achieved by this prosthesis.

WEDNESDAY
AFTERNOON

ABSTRACT 27

MINIMALLY INVASIVE RADIAL ARTERY HARVESTING UNDER DIRECT VISION

G.Gelpi, M.Lemma, A.Mangini, A.Innorta, C.Antona
Dept.of Cardiovascular Surgery, L.Sacco Hospital, Milan, Italy

OBJECTIVE: Evaluation of a new method for radial artery (RA) harvesting under direct vision through a minimally invasive approach.

METHOD: From August 2002 in 35 pts the RA was harvested under direct vision through a skin incision of 3.5 ± 0.3 cm at the distal third half of the forearm with the aid of the RadLITE system (Genzyme, USA). In 8 pts a second incision of 2 cm was needed proximally in the forearm, to reach the full length of the RA.

RESULTS: The mean length of the RA harvested was 18.2 ± 0.9 cm and in all cases except two was anastomized proximally to the LITA as a Y-graft. These technique allowed to perform 3.1 ± 0.7 anastomosis/pt and 1.7 ± 0.4 anastomosis/pt with RA. No death or MI occurred postoperatively. 20 pts underwent a pre-discharge angiogram that showed the patency of all anastomosis. Postoperatively no pts revealed ischemia or motor dysfunction of the thumb; only two pts complained a transient abnormal sensation of the dorsal part of the tenar.

CONCLUSIONS: This new approach is safe and effective both for the patient and for the RA; it allows harvesting the RA under direct vision, alone and through a minimally invasive skin incision.

ABSTRACT 28

TECHNICAL ASPECTS OF HARVESTING THE RADIAL ARTERY WITH HARMONIC SCALPEL

Locker C, Ben-Gal Y, Paz Y, Lev-Ran O, Uretzky G, Mohr R.
Dept. of Cardiothoracic Surgery, Tel Aviv Sourasky Medical Center,
Tel Aviv, Israel.

BACKGROUND: Harvesting the Radial Artery (RA) with Harmonic Scalpel (HS) reduces spasm induced by surgical handling. Topical exposure to Regitine exerts an additional effect of vasodilatation.

METHODS: RA was harvested as a pediculated vessel with HS in 100 patients undergoing myocardial revascularization. A fasciotomy of the pedicle was carried out after harvesting. Composite graft with reverse free RA on in situ left internal thoracic artery (LITA) was prepared before construction of distal coronary anastomoses. The RA was then put in a syringe filled with Regitine (Phentolamine Methansulphonic) (0.07 mcg/ml) for 10 minutes.

RESULTS: The mean number of grafts/patient was 3.0. The mean number of radial anastomoses was 2.0/patient. LITA free flow was: 105 ± 34 ml/min. Regitine increased radial free flow from 60 ± 35 to 82 ± 30 ml/min ($p < 0.05$). Ten patients underwent postoperative coronary angiography. All radial anastomoses were patent.

CONCLUSION: The compound effect of RA harvesting with the harmonic scalpel and topical treatment with the α -blocking agent Regitine) increases RA free flow and significantly decreases intra-operative spasticity.

WEDNESDAY
AFTERNOON

ABSTRACT 29

TOTAL MYOCARDIAL REVASCULARIZATION ON THE BEATING HEART VIA LEFT THORACOTOMY

Maximo Guida, M.D., Giuseppina Pecora, M.D., Gustavo Muñoz, M.D.,
Alejandro Acuña, M.D.
Centro Medico Guerra Mendez-FUNDACARIO; Valencia, Carabobo, Venezuela

We report herein the case of 56-year-old male patient with triple vessels coronary disease and increased body-mass index (36, 81), scheduled for elective coronary artery revascularization.

To avoid the morbidity associated with median sternotomy, we decided for a Left Thoracotomy approach. The Left Internal Thoracic Artery (LITA) and Right Radial Artery were dissected in Skeletonized fashion and anastomosed for a composite "Y" graft. Two Saphenous Vein Grafts (SVG) were anastomosed to the Ascending Aorta using the Symmetry Aortic Connector device. Four By-Pass grafts on the beating heart were performed: LITA to LAD, Radial to Diagonal Branch, Saphenous vein graft to Marginal branch and to Right Coronary artery with the left lung collapsed during the procedure.

The surgery was succesful, with the patient extubated on the OR and the postoperative course uneventful.

A video recording of the technique used will be presented.

ABSTRACT 30

**COMBINED TREATMENT OF AORTIC TYPE A DISSECTION:
ASCENDING AORTA REPAIR AND PLACEMENT OF A STENT
IN THE DESCENDING AORTA**

Jazayeri S., Tatou E., Gomez MC., Bouchot O., Saleh M., Renaud C., Brenot R., David M.

Department of Cardiovascular Surgery, Dijon University Hospital, Dijon, France

WEDNESDAY
AFTERNOON

INTRODUCTION: The established treatment modality of acute Stanford type A dissection includes repair of the ascending aorta and a variable part of the aortic arch, leaving the descending aorta untreated. We report a simultaneous approach of open repair of the ascending aorta with transluminal placement of a stent in the descending aorta to minimize the consequences of an untreated descending aorta.

METHODS: Two cases of aortic dissections type A with the entry port in the descending aorta in one case and in the aortic arch in second one were treated by replacement of the ascending aorta (and aortic arch in second case) and placement of a stent in descending aorta with a new device under circulatory arrest and deep hypothermia.

The device consists of a stent DJUMBODIS (r) (Saint Come-chirurgie, Marseille, France) mounted on a compliant balloon (fig 1). This stent is made of a Steel 316 L, and can be adapted to the shape of the aortic arch or descending aorta. Three different lengths are available 4, 9 and 14 cm. The device has a diameter of 9 mm.

RESULTS: The early results were satisfactory with a complete thrombosed false lumen in one case, and a partial thrombosed false lumen in another one, on postoperative transesophageal echocardiography control. A follow up computed tomographic chest scan was done at 12 months for the first case and 7 months for the second case, which confirmed the good surgical results.

CONCLUSION: This preliminary study shows that combined surgical and endovascular treatment of acute type a dissection is feasible and at least partial thrombosis of the false lumen can be achieved, potentially minimizing the risk of further dilatation or rupture. The early results are encouraging but more cases and long-term results are warranted to demonstrate the effectiveness of this new combined treatment modality.

ABSTRACT 31

**NEW APPROACHES FOR PORT-ACCESS CARDIAC SURGERY -
JAPANESE EXPERIENCES**

Ryohei Yozu, H. Shin, Y. Iino, K. Anzai and T. Maehara
Keio University, Dept.of Surgery. Tokyo Japan

We will describe our experience with port-access cardiac surgery conducted under the support of our new technology.

The author developed a direct endoaortic balloon (Yozu balloon), which is a triple-lumen balloon catheter of 3.6mm in outer diameter and 40 cm in full length. The balloon is inserted directly into the ascending aorta. Injection of cardioplegia and aortic vent can be conducted. Also, we introduce a modified Cosgrove flex clamp to apply in small-incision surgery, aiming at a less invasive procedure. The modified point is that the original, united Cosgrove flex clamp can be divided into the handle part equipped with a ratchet, and the shaft part equipped with a clamp jaw.

By this modification, it became possible to apply the Cosgrove flex clamp transthoracically like a Chitwood sliding aortic clamp; that is, it became possible to conduct aortic clamping more safely and securely through this 8 mm hole. Of the 82 pts. who underwent port-access MICS (ASD 46, MVP 30 others 6). No pts. died, and outcomes were uniformly favorable. All pts. returned to work early. The average of pts.' postoperative hospital stay is 5 days (shortest: 3 days). None of these pts. have been readmitted.

In view of future technological progress, we can expect the gradual but wide popularization of this method.

ABSTRACT 32

**SYNCRUS: A NEW SYSTEM FOR POSTOPERATIVE AF
CARDIOVERSION**

Klein, Peter

University Hospital Frankfurt AM Main; Frankfurt, Germany

Atrial fibrillation (AF) commonly occurs following open heart surgery. Although the prognosis of this dysrhythmia is generally good, hemodynamics may be impaired during the AF period and mobilization is delayed. Various studies have demonstrated increased length of hospital stay caused by AF.

Since 2002 a new device for treatment of postoperative AF has been available. Via SYNCRUS heart wires (Guidant Inc., Santa Clara, CA) implanted on the left and right atrium during open heart surgery low-energy internal cardioversion shocks can be applied postoperatively. The SYNCRUS system is FDA approved and CE marked. Effectiveness and safety have been demonstrated in a pilot study. Especially a reduction in the length of AF periods was achieved by the heart wire system.

The video demonstrates the surgical technique of implantation of SYNCRUS wires during open heart surgery (CABG operation) in the first part. The second part of the video shows the performance of internal cardioversion to terminate postoperative AF on the normal ward. Technical details and safety requirements are included in the video tape

WEDNESDAY
AFTERNOON

ABSTRACT 33

IMPLANTATION TECHNIQUE OF A NEWLY DESIGNED STENTLESS MITRAL VALVE

Jose L. Navia, Kazuyoshi Doi, Mario Garcia, Kiyotaka Fukamachi, Pablo Ruda Vega, Michael Kopcak, Eugene H. Blackstone, Patrick M. McCarthy, Delos M. Cosgrove III.

The Cleveland Clinic Foundation, Cleveland, OH

OBJECTIVE: To demonstrate the feasibility and reliability of an implantation technique for a newly designed stentless mitral valve (SMV).

METHODS: A bovine pericardial bileaflet SMV with chordae-like structure resembling the native mitral valve was implanted in a sheep model through a left thoracotomy. Under cardiopulmonary bypass, the mitral valve leaflets and chordae were excised through a left atriotomy. The size of the mitral annulus (MA) and the distance between the mitral commissure and the papillary muscle (PM) were measured to determine the size and height of the SMV. Each chord of the SMV was sutured to the head of the PM, and the inflow orifice of the SMV was fixed to the native MA.

RESULTS: Postoperative echocardiography showed no to trivial mitral regurgitation, large effective orifice area and low transvalvular pressure gradient (Rest: 1.8 ± 1.1 , Dob: 2.3 ± 1.2) in six acute animal models.

CONCLUSIONS: The implantation technique was simple, feasible, and maintained physiologic MA-PM continuity. The new SMV showed an excellent valvular performance

Thursday, March 20, 2003

Scientific Session I
Three Best Original Presentations

Abstracts 34, 35, 36

Video Library
Abstracts 37, 38, 39

(Grand Ballroom East)

THURSDAY
MORNING

ABSTRACT 34

INTEGRATED MINIMALLY INVASIVE CORONARY ARTERY BYPASS GRAFTING AND ANGIOPLASTY. A CLINICAL AND ANGIOGRAPHIC FOLLOW-UP

Marek Cisowski, Rafik AbuSamra, Janusz Drzewiecki*, Wojciech Kruczak**, Krzysztof Toczek**, Sławomir Szczesniak, Andrzej Bochenek
First Department of Cardiac Surgery,*First Department of Cardiology,**Department of Cardio-anesthesiology Medical University of Silesia, Katowice, Poland

BACKGROUND: Minimally invasive coronary artery bypass (MICAB) through the anterolateral minithoracotomy has become a promising therapeutical option in patients (pts) with lesion in left anterior descending artery (LAD) – especially in multi-morbid, elderly and re-operated pts with type C or B lesions. To expand the benefits of MICAB concept to patients with multivessel disease, a hybrid myocardial revascularization procedure (HMR) combining minimally invasive surgery of the LAD with percutaneous coronary intervention (PCI) procedures for additional coronary lesions has recently been introduced.

METHODS: Between January 1999 and February 2002, 62 pts (46 male, 16 female, mean age $54,8 \pm 20,1$ years) underwent a HMR procedure. MICAB with endoscopic left internal thoracic artery (LITA) harvesting followed by PCI for additional coronary lesions – percutaneous transluminal coronary angioplasty (PTCA) was performed in 16 pts (26%) and stenting in 46 pts (74%). Angiographic assessment of graft patency was performed in all pts. Clinical follow-up period was 6 to 40 months.

RESULTS: There were no early and late deaths. Baseline Canadian Cardiology Society (CCS) class was $2,8 \pm 0,7$ versus $1,1 \pm 0,9$ ($p < 0,001$) 30 days after HMR procedure. There were no major acute in-hospital cardiac events. Angiographic studies showed patent LIMA-LAD graft in 62 pts (100%). We showed good quality of anastomosis in 61 pts (98.3%). There was a moderate graft stenosis in one patient (1.7%). At long term follow-up, the rate of major cardiac events was 11.3%. Six pts (9.7%) developed restenosis after PCI, and one patient (1.6%) developed significant stenosis in site of LITA-LAD anastomosis - PCI were performed successfully.

CONCLUSIONS: The hybrid procedure is a safe and effective method for complete revascularization in selected pts with multi-vessel coronary artery disease. This method allows the performance of complete revascularization with minimization of surgical trauma. So far, long-term results of HMR are limited by the results of PCI.

ABSTRACT 35

SKELETONIZED RIGHT GASTROEPIPLOIC ARTERY AS A THIRD ARTERIAL CONDUIT; EARLY AND MIDTERM RESULTS AFTER OFF-PUMP TOTAL ARTERIAL REVASCULARIZATION

Ki-Bong Kim, Hyun-Joo Lee, Chang Hyun Kang, Woo-Ik Chang
Seoul National University Hospital, Seoul, Korea

BACKGROUND: The aim of this study was to evaluate the early and midterm results of off-pump total arterial revascularization using the skeletonized right gastroepiploic artery (RGEA) as a third arterial conduit.

METHODS: We prospectively analyzed 86 patients who underwent off-pump total arterial revascularization using bilateral internal thoracic arteries (ITA) and RGEA. The RGEA was used as in situ graft in 74 patients, composite graft in 8 patients, and free graft in 4 patients. Postoperative coronary angiographies were performed before discharge in 83 patients, and at postoperative one year in 70 patients.

RESULTS: The RGEA showed a significantly higher free flow (100 ± 78 ml/min) than that of right ITA (92 ± 46 ml/min) or left ITA (89 ± 41 ml/min), which was measured before anastomosis ($p < 0.05$). The total number of distal anastomoses was 3.8 ± 0.7 . The number of distal anastomoses per bilateral ITAs was 2.8 ± 0.7 , and the number of distal anastomosis per RGEA was 1.0. There were three mortalities including one operative mortality. Two late mortalities were not related to cardiac events. Early postoperative morbidities were atrial fibrillation in 10 patients, bleeding reoperation in 2 patients, mediastinitis in 2 patients, and perioperative myocardial infarction in 1 patient. Postoperative coronary angiographies showed the early patency rate of 98.3% (228 / 232) for ITA and 97.6% (81/83) for RGEA, respectively ($p = ns$), and the one-year patency rate of 94.9% (185 / 195) for ITA and 91.4% (64/70) for RGEA, respectively ($p = ns$).

CONCLUSIONS: The skeletonized RGEA demonstrated excellent early and midterm patency rates and could be used as a third arterial graft following the bilateral ITAs.

THURSDAY
MORNING

ABSTRACT 36

MULTI-VESSEL, ALL-ARTERIAL, OFF-PUMP SURGICAL REVASCULARIZATION WITHOUT DISRUPTION OF THE THORACIC SKELETON.

Thomas A. Vassiliades, Jr., MD

BACKGROUND: Multi-vessel, minimally traumatic coronary artery bypass grafting continues to evolve.

METHODS: Thirty-eight patients underwent all-arterial, off-pump revascularization through incisions avoiding manipulation of the thoracic skeleton. The technique consisted of a unilateral approach to bilateral thoracoscopic internal mammary artery harvesting followed by a non-rib spreading, muscle-sparing opening in the soft tissue of the thorax. A thoracoscopic suction device and stabilizer exposed and steadied the target coronary arteries under the chest opening. The anastomoses were then constructed off-pump through the natural width of the intercostal space.

RESULTS: The mean number of grafts per patient was 2.2 ± 0.4 . Transit time flow measurements confirmed a patent graft before closure in every patient. The mean operating time was 4.4 hours (range 3.4 to 5.6). Hospital length of stay was 2.6 ± 1.9 days. There was no early or late mortality. Complications were primarily pulmonary (6 patients, 15.8 %). Dobutamine stress echo at three months verified successful target vessel revascularization in 97.4% (37/38) of patients.

COMMENT: A grafting approach that avoids any manipulation of the thoracic cage offers significant patient value; previously this was limited to single-bypass cases.

ABSTRACT 37

AORTIC VALVE-SPARING OPERATION ACCORDING TO DAVID IN A PATIENT WITH AORTIC ROOT ANEURYSM USING A NEW PROSTHESIS FOR ANATOMICAL RECONSTRUCTION OF THE SINUSES OF VALSALVA

Friedrich-Christian Riess
Albertinen Hospital, Hamburg, Germany

OBJECTIVE: Valve-sparing operations in patients with aortic root aneurysm seem to be the treatment of choice because of good hemodynamic results and avoidance of anticoagulation. However, resection of aortic sinuses and substitution by a straight Dacron prosthesis with diminished compliance result in increased stress to the cusps.

METHODS: A video is presented, showing an aortic valve-sparing operation according to David in a patient with aortic root aneurysm using a new aortic prosthesis for anatomical reconstruction of the sinuses of Valsava by means of a new aortic root Dacron graft (Gelweave Valsalva, Vascutek, and Renfrewshire, Scotland).

RESULTS: The operation was performed without complications. Due to the special design, which provides compliance in a horizontal plane and recreates the anatomy of the sinuses of Valsalva the implantation of both coronary arteries was easy to perform with less dissection of the coronary arteries. Postoperative MRT assessment demonstrated a competent aortic valve and anatomical reconstruction of the sinuses of Valsalva.

CONCLUSION: A new aortic root Dacron graft was used safely and effectively in a patient with aortic root aneurysm, for aortic valve-sparing operation according to David allowing an anatomical reconstruction of the sinuses of the Valsalva.

THURSDAY
MORNING

ABSTRACT 38

COELIOSCOPIC HARVESTING OF THE GASTROEPIPLOIC ARTERY FOR MIDCAB

Etienne, Pierre Yves
Clinique St. Luc; Namur, Belgium

BACKGROUND: Utilisation of the right gastroepiploic artery (RGEA) has allowed arterial revascularisation of the right coronary branches with good permeability results. Anyway, harvesting of this vessel implicates opening of the abdominal cavity with subsequent possible complications.

METHODS: 7 patients underwent totally coelioscopic harvesting of the right gastroepiploic artery for coronary artery bypass. Artery was liberated with help of ultrasonic coagulation and right coronary artery exposed after xyphoid resection. Usual hole was made into the diaphragm and anastomosis was performed on the beating heart to the right coronary artery or the posterior descending artery. 6 patients underwent concomitant thoracoscopic harvesting of the left internal mammary artery and grafting of the LAD by a small parasternal thoracotomy in the fourth left intercostal space.

RESULTS: No patient died or suffered postoperative infarction. The first 3 patient underwent postoperative angiography showing good patency of the grafts. Mean follow up was 13 months. No patient died or presented recurrent angina. All grafts were controlled by echo-doppler evaluation and were found to be patent.

CONCLUSIONS: RGEA can be used after coelioscopic harvesting. Combination with endoscopic harvesting of the left internal mammary artery allows complete MIDCAB arterial revascularisation in selected cases with excellent midterm results.

ABSTRACT 39

OFF PUMP LONG ONLAY PATCH ANGIOPLASTY TO THE LAD USING LEFT INTERNAL MAMMARY ARTERY

Shuichiro Takanashi, MD, Toshihiro Fukui, MD, Shin Yamamoto, MD ,
Yasuyuki Hosoda, MD
Department of Cardiovascular Surgery, New Tokyo Hospital, Chiba, Japan

AIM: Surgical treatment for diffusely diseased coronary artery was considered to be a relative contraindication for OPCAB and the long onlay patch grafting with OPCAB technique has not been described in our knowledge.

MATERIALS AND METHODS: Two sets of tissue stabilizers (Octopus-3, Medtronic, Minneapolis MN) were placed longitudinally along the target coronary artery. This allowed us to performed surgical angioplasty and bypass grafting without cardiopulmonary bypass support (Double Octopus technique).

RESULTS: We report our early experience of off-pump long onlay bypass grafting using left internal mammary artery in a case of diffuse disease of the left anterior descending coronary artery. Patients who have severe diffuse coronary lesion and are high risk for cardiopulmonary bypass will benefit from this technique.

THURSDAY
MORNING

Thursday, March 20, 2003

Original Presentations Breakout Session I
Enabling Technology for Coronary Revascularization

Abstracts 40 - 49

(Le Mans Room)

THURSDAY
AFTERNOON

ABSTRACT 40

EVALUATING CORONARY ARTERY BYPASS GRAFTING

Folliguet, Thierry

Institut mutualiste montsouris; Paris, France

OBJECTIVES: To evaluate coronary artery bypass grafting (CABG) performed with minimal extracorporeal circulation (MECC) either as beating heart hemodynamic support or under cardiac arrest with warm cardioplegia.

MATERIAL AND METHOD: From September 2000, to September 2002, 243 consecutive patients were operated with a closed CPB incorporating a centrifugal pump (RotaFlow JOSTRA) and a membrane oxygenator (QUADROX JOSTRA). The whole system is covalently heparine coated, and the priming is reduced to 400ml. The system was used either as a complete CPB in patients with ejection fraction (EF) > 30% (n=203), or as a hemodynamic support device on the beating heart in patients with an EF < 30% (n=40). In a prospective substudy the MECC group with cardioplegia was compared with a control group (40 vs 40) in order to analyze thrombocytes, PaO₂/FiO₂, leucocytes, CRP, platelets, transfusion. All venous anastomosis were done before bypass, which were conducted in normothermia. Preoperative risk factors showed a higher risk group in the beating heart as compared to the cardioplegia group.

RESULTS: Operative data were respectively for the cardioplegia and the beating heart: distal anastomosis 2.9 and 2.5, aortic clamp time 42 min, pump time 58 and 64 min. Hematology data were respectively: preoperative hematocrit 40% and 35%, peroperative hematocrit 31% and 30%, peroperative blood transfusion 2% and 10%, total blood transfusion 30% and 47%. Inflammatory response and transfusion was lowered in the MECC group with cardioplegia (n=40) as compared with an open system (n=40) as evidenced by a 15% reduction in CRP, and a 20% reduction in leucocytes count, and a 20% reduction in transfusion. Also postoperative platelets count was 15% higher in the MECC group. Postoperative data were respectively: intubation time 10h and 12h, ICU stay 2.8 d and 3.2d, MI 1%, inotropic support 2.4% and 18%, cerebrovascular event 1% and 2.3%, hospital mortality 1.4% and 5%.

CONCLUSION: MECC allows complete and safe coronary revascularisation in good and high risk patients. It provides a reduction in hemolysis, hemodilution, inflammation and intraoperative transfusions can be reduced.

ABSTRACT 41

THE TOTAL MINIMIZED EXTRACORPOREAL CIRCULATION : AN IMPORTANT BENEFIT FOR CORONARY ARTERY BYPASS GRAFTING IN JEHOVAH WITNESSES

Claude Vaislic MD, Olivier Bical MD, Claude Farge MD, Didier Gaillard MD, Olivier Ponzio MD, Yves Ollivier MD, Youcef Abdelmoumen MD, Bruno Robine MD, Gérard Souffrant MD, Touami Bouharaoua MD

Introduction: Jehovah Witnesses who require cardiac surgery represent a challenge to the physician because of the patient's refusal to accept blood transfusion. As Coronary artery bypass grafting (CABG) is performed by most surgeons under cardio pulmonary bypass (CPB) which has potentially deleterious effects on hemostasis, we used a new concept called Minimal Extra Corporeal Circulation (MECC) that includes an heparin coated tubing, a centrifugal pump and an oxygenator. There are no venous reservoir or vent, and suction is used through the cell saver.

Hypothesis: We assessed the hypothesis that MECC in combination with a low volume blood cardioplegia preserves more hemoglobin than conventional CPB in standard CABG.

Methods: In 20 patients of Jehovah witness faith undergoing CABG with the use of MECC and an intermittent warm blood cardioplegia, clinical and biological data as well as parameters of hemolysis (plasma Hb) and myocardial damage (troponin-T) were determined. The results were compared to those of a control group of 20 patients who were operated on with standard CPB.

Results: Demographic, hemodynamics, number of anastomoses, CPB and Cross-clamp time were comparable between the groups. MECC patients demonstrated significantly lower peak level of plasma Hb (35.4±15 vs 21.8±114 mg/dl), troponin T (0.12±0.4 vs 0.65±0.7 ng/ml), higher minimum hematocrit level during CPB (30±7% vs 23±6%) and higher hemoglobin level 2 days after surgery (13±3g/100ml vs 9.4±0.98 g/100ml) for preoperative value non significantly different.

Conclusion: In conclusion the use of MECC instead of conventional CPB reduces hemolysis, hemodilution, blood loss, and myocardial damage, and is a valuable adjunct to treat Jehovah Witness patients.

THURSDAY
AFTERNOON

ABSTRACT 42

HEMODILUTION DURING OPCAB: CAN WE IMPROVE FLOW AND REDUCE EARLY HYPERCOAGIBILITY?

Mustafa Guden, Ilhan Sanisoglu, Ertan Sagbas, Mehmet Ergenoglu, Belhhan Akpinar
KHU, Florence Nightingale Hospital, Istanbul, Turkey.

OBJECTIVES: We compared intraoperative coronary graft flows performed on and off pump and evaluated the effect of hemodilution on graft flows in off-pump CABG patients using transit time flow measurements.

MATERIAL AND METHODS: During 2 years, 300 CABG patients were enrolled in a prospective randomised way. Group 1 consisted of 100 patients operated with standard CPB. Group 2 consisted of 100 patients operated with off-pump CABG. Group 3 consisted of 100 patients operated with off-pump techniques under controlled hemodilution (Htc:24-26.)

RESULTS: Mean flows for LAD ($p < 0.05$), RCA ($p < 0.05$) and Circumflex artery ($p > 0.05$) were lower in group 2 patients. Group 3 patients had significantly higher graft flows compared to group 2 patients. The pulsatile index values were similar in all groups. Coronary angiography, performed one week after the surgery in 25 patients in each group revealed similar ITA patencies, but lower SVG patencies for group 2 ($p > 0.05$)

CONCLUSION: We hypothesize that hemodilution can be used as a tool to improve graft patency during the early 'hypercoagulable period' in OPCAB patients.

ABSTRACT 43

PRECiSe (PRIMING REDUCED EXTRACORPOREAL CIRCULATION SETUP) WITH THE DELTASTREAM DIAGONAL PUMP.

Sven Beholz, Michael Kessler, Wolfgang Konertz
Department of Cardiovascular Surgery, Charité, Humboldt-University Berlin,
Germany

PURPOSE OF THE STUDY: Different systems low priming systems limited to CABG have been introduced. We describe PRECiSe (Priming reduced extracorporeal circulation setup), a new low priming system which supplies all features of cardiopulmonary bypass.

MATERIAL AND METHODS: PRECiSe incorporates the Deltastream diagonal pump, which pumps blood from the right atrium to the aorta via a membrane oxygenator and a filter; the system is placed beneath the patient's head resulting in extremely short tubings. A reservoir allows the use of suckers and vents. Autologous blood priming further reduces hemodilution. In the safety study the system was used for extracorporeal circulation in 11 patients undergoing CABG without adverse events. By use of PRECiSe mean priming was reduced to 268.5 ml resulting in minimal hemodilution and transfusion requirements.

CONCLUSION: The use of PRECiSe for extracorporeal circulation in CABG is safe and reduces priming volume as well as transfusion requirements. Further studies are necessary to investigate the clinical benefit for the patients as well as the use of the system in open heart procedures.

THURSDAY
AFTERNOON

ABSTRACT 44

PRACABG (PERFUSION ASSISTED OPCABG) - CHEAP ENABLING TECHNOLOGY FOR OPCABG

David Jayakar MD, Dennis Sobieski CP, V. Jeevanandam MD
University of Chicago; Chicago, IL, USA

PURPOSE: Right Heart support during OPCABG is well documented to achieve hemo-dynamic stability. Currently the most widely used device ParaFlow (A-Med) costs \$ 1000 per case for the hospital. We have designed a simple pump using 3/8 inch tubing and have reduced this cost to \$ 70 per case.

METHODS: We make a pump using 3/8 inch tubing and use one of the roller pump that is normally used for cardiomy suction. The bypass is done between right atrium to Pulmonary artery using standard venous and arterial cannulas. 10 patients were done using this procedure. 43 grafts were done. 55% required no pressor support.

RESULTS:

Coronary Vessels	Support	MAP	CO	SVO2
Diag	Off	64	4.5	69
	On	72*	5.2*	74
OM	Off	59	3.2	68
	On	70*	5.0*	74
PDA	Off	62	4.2	70
	On	68	5.2*	72

*P<.05

CONCLUSION: We have achieved a cost effective RV support that enables OPCABG. Also this technology embraces our perfusionist actively in managing these complex patients as if we have to convert they would prime the pump and will be there to go on bypass. PRCABG is cost effective and practical in the current OPCABG market.

ABSTRACT 45

AUGMENTING LEFT VENTRICULAR PRELOAD WITH A MINIATURE RIGHT HEART SUPPORT SYSTEM IMPROVES CARDIAC OUTPUT AND STROKE VOLUME DURING BEATING HEART CORONARY ARTERY BYPASS GRAFTING

Dwight C. Lundell(1) and John D. Crouch(2)
 (1) Cardiac Care Center LLC, Mesa, AZ, USA
 (2) St. Luke's Medical Center, Milwaukee, WI, USA

BACKGROUND: Certain manipulations to access anastomotic sites during beating heart CABG compromise hemodynamics that may impact end-organ perfusion and limit patient selection. Evidence suggests right heart support (RHS) augments left ventricular preload and improves hemodynamics.

METHODS: Beating heart surgery (BHS) was performed on 43 patients with LV preload managed with RHS (A-Med Systems, Inc., West Sacramento, CA). Average age was 65; average EF was 44%. Cardiac output (CO), stroke volume (SV), mean arterial pressure (MAP), and cardiac index (CI) were taken at baseline, during each anastomosis with optimal heart position, and when RHS was interrupted prior to heart release.

RESULTS: One-hundred forty-eight vessels were grafted. Reductions in CO, SV, MAP, and CI were consistent for all target vessels when RHS was stopped, most evident for posterior and lateral target vessels. There were no surgical interruptions, bypass conversions, intraoperative IABPs, or deaths.

Target Vessel Average % Reduction with RHS Off

	CO	SV	MAP	CI
Circumflex	19.3	20.1	15.8	19.3
OM-1	28.3	27.3	20.5	28.3
PDA	22.4	20.3	14.7	22.2
OM-2	13.6	12.5	11.2	13.6
Diagonal	13.9	14.6	7.2	13.9
RCA	14.6	17.1	10.2	14.6
LAD	13.0	15.3	8.6	13.0

CONCLUSION: Augmenting LV preload improves hemodynamics during BHS and may improve end-organ perfusion.

THURSDAY
AFTERNOON

ABSTRACT 46

BIVENTRICULAR PACING ENABLES OPCABG IN HIGH RISK PATIENTS

David Jayakar, MD; Nhung T. Lam, MD; Valluvan Jeevanandam MD, Solomon Aronson, MD
University of Chicago Hospitals, Chicago IL

OBJECTIVE: With the improvement in the techniques of off pump coronary artery bypass surgery (OPCAB), patient with multiple co-morbidity undergo surgery. Many of these patients have various degree of occult interventricular conduction delay. During complex manipulation of the heart to bypass the lateral and posterior vessels, ventricular conduction delay caused dysynchrony. We have used Biventricular Pacing (BVP) to achieve hemodynamic stability. Intraoperative TEE with 2D and tissue Doppler imaging was used to measure peak systolic tissue velocity, strain and strain rate as index of myocardial performance changes before and after biventricular pacing.

METHODS: Patients scheduled for elective off-pump cardiac surgery with ischemic cardiomyopathy, were deemed potential candidate for biventricular pacing. All patients received invasive lines and cardiac output monitoring and a comprehensive intraoperative TEE exam. Prior to manipulations, two epicardial pacing leads were placed on the heart, one on the lateral wall of the right ventricle and one on the inferior wall of the left ventricle. The patient was then paced at 90 bpm at DDD pacing mode.

RESULTS: We had a 65% increase in Cardiac Index, with 25% increase in EF. The Septal Peak Velocity increased by 20% and the Time to peak decreased by 50 milli seconds. The time to reach maximum strain and peak velocity were also noted to decrease. All the patients were completed as OPCABG without any complications. The cases above demonstrate that biventricular pacing can be used safely and effectly in the acute intraoperative setting to achieve better hemodynamic control and improve cardiac performance.

CONCLUSION: We have demonstrated that biventricular pacing can be used safely and effectly in OPCABG to achieve better hemodynamic control and improve cardiac performance. These data support our hypothesis that acute left ventricular performance improvement is a consequence of improved interventricular septal synchrony between the LV and RV.

ABSTRACT 47

INDOCYANINE GREEN LASER CORONARY ANGIOGRAPHY: A NOVEL METHOD OF INTRAOPERATIVE PATENCY ASSESSMENT

Nimesh D. Desai, M.D., Marc P. Pelletier, M.D., Hari R. Mallidi, M.D., Gideon Cohen, M.D., Bernard S. Goldman, M.D., Stephen E. Frenes, M.D.
Division of Cardiac Surgery, Sunnybrook and Women's College Health Sciences Centre/University of Toronto. Toronto, Canada.

BACKGROUND: The proliferation of minimally invasive techniques and anastomotic connectors in cardiovascular surgery has increased the need for intraoperative patency assessment. The purpose of this investigation was to determine the safety and technical feasibility of a new method of intraoperative angiography.

METHODS: This technique uses the fluorescent properties of a dye compound that is excited with dispersed laser light to create an angiographic depiction of the graft, native vessel, and anastomosis. Indocyanine green dye (ICG) is a fluorescent compound which can be administered intravenously or intra-arterially. The dye absorbs the dispersed laser light in the near infrared region at 806nm and emits light at 830nm. A CCD video camera digitally records the images.

RESULTS: Forty patients have been assessed at our institution with ICG angiography. Technical success improved from 40.6% in our first five patients to greater than 80% in our current patients. In this initial series, one patient (2.5%) was found to have a twisted vein graft that was revised successfully. No adverse effects from the laser or dye compound occurred.

CONCLUSIONS: Indocyanine green angiography is safe and provides excellent visualization of graft, anastomosis and native vessel. This method of angiography may become an essential tool for routine patency assessment.

THURSDAY
AFTERNOON

ABSTRACT 48

INSTANT INTRAOPERATIVE QUALITY ASSESSMENT OF BYPASS GRAFTS BY DIRECT LASER ANGIOGRAPHY

K. Matschke, U. Kappert, J. Schneider, V. Gulielmos
Heart Center Dresden University Hospital, Dept. of Cardiac Surgery;
Dresden, Germany

INTRODUCTION: So far, no intraoperative digital method for an instant quality assessment has been proposed to judge the functioning of bypass grafts in coronary artery surgery. Coronary angiography is always correlated to certain risks and is not always at hand. We present a simple non-invasive direct method of fluorescence laser angiography for the quality control of coronary anastomoses with a minimal OR setup.

METHODS: We derived a method from plastic surgery for the measurement of blood flow and changed the procedure so that the contrast medium could be applied directly to the coronary artery grafts. Our protocol is based on the intraoperative application of an albumin adhering substance, which can be measured by means of its fluorescing nature via a digitally laser enhanced camera.

RESULTS: A first series of 5 patients suffering from coronary artery disease was operated on pump in order to evaluate the efficacy of this new method. Graft patency, run-off and further lesions can be judged with direct laser angiography (DLA).

CONCLUSION: Our preliminary results are positive, represent first steps in the development of an intraoperative quality assessment of bypass grafts by DLA and are aiming at establishing a safety standard for OPCAB surgery in addition to flow-measurement.

ABSTRACT 49

INTRAOPERATIVE COLOR DOPPLER ULTRASOUND ASSESSMENT OF LIMA-LAD ANASTOMOSES DURING OFF-PUMP CORONARY ARTERY BYPASS SURGERY CORRELATES WITH ANGIOGRAPHIC EVALUATION AT EIGHT MONTHS FOLLOW UP

Ole Tjomsland, Rune Wiseth, Nicola Vitale, Arve Tromsdal, Stein O. Samstad, Alexander Wahba, Rune Haaverstad.
St Elisabeth Heart Center, Norwegian University of Science and Technology, Trondheim, Norway.

OBJECTIVE: The study was performed to evaluate the correlation between intraoperative color Doppler ultrasound assessment of LIMA-LAD anastomoses performed on beating heart and the angiographic assessment after eight months.

METHODS: Twenty patients (M/F 15/5, age 63 ± 9) underwent epicardial color Doppler imaging with a 10 MHz linear array GE Vingmed transducer/GE Vingmed System FiVe. Coronary angiography after 245 (128-320) days allowed assessment of TIMI flow and Fitz-Gibbon grading in all patients. Detailed quantitative coronary angiography (QCA) was performed in 10 patients measuring LAD diameter at the toe of the anastomosis (D1) and downstream LAD (D2).

RESULTS: Intraoperative ultrasound revealed 19 (95%) patent LIMA-LAD anastomoses. A $> 50\%$ anastomotic stenosis was detected and subsequently successfully revised. Angiography showed TIMI-III flow and Fitz-Gibbon grade A in 18 grafts, one anastomosis had Fitz-Gibbon grade B stenosis and one was occluded. The D1/D2 ratios of the LAD measurements assessed with intraoperative ultrasound and follow-up QCA correlated significantly ($r\text{-square} = 0.62$, $p < 0.01$).

CONCLUSION: Intraoperative color Doppler ultrasound allows a detailed evaluation of LIMA-LAD anastomoses during off-pump surgery, which correlates significantly with angiographic evaluation after 8 months. Epicardial ultrasound may reduce the risk of impaired graft patency caused by technical errors.

THURSDAY
AFTERNOON

Thursday, March 20, 2003

Original Presentations Breakout Session II

Abstracts 50 - 59

Heart Failure: New Devices and Procedures

(Brittany / Champagne Rooms)

THURSDAY
AFTERNOON

ABSTRACT 50

**OFF-PUMP MITRAL VALVE REPAIR USING THE COAPSYS DEVICE:
ACUTE QUANTITATIVE ECHOCARDIOGRAPHIC RESULTS**

M. Inoue, Z. Popovic, K. Doi, S. Schenk, Y. Ootaki, H. Nemeah, M. Kopeck,
R. Dessoffy, J. Thomas, P. McCarthy, K. Fukamachi
Cleveland Clinic Foundation, Cleveland OH

BACKGROUND: Functional mitral regurgitation (MR), which frequently accompanies dilated cardiomyopathy, is associated with dilatation of the mitral valve annulus and/or lateral/apical displacement of the papillary muscles. This study evaluated the ability of the Myocor Coapsys device to reduce MR acutely in a canine model of functional MR.

METHODS: The Coapsys device was implanted in 8 dogs in which rapid ventricular pacing induced both cardiomyopathy and significant functional MR. The device consists of two epicardial pads connected by a sub-valvular chord. The posterior pad was positioned at the annular level and centered on the posterior leaflet. The sub-valvular chord bisected the valve coaptation line. The device was sized by reducing its dimension, drawing the posterior annulus toward the anterior annulus until MR was maximally reduced. Epicardial echocardiography was performed during the implant procedure prior to and after sizing of the device. Effective regurgitant orifice area (EROA) was calculated using the continuity equation. MR jet area and the ratio of MR jet area to left atrial (LA) area were measured. Regurgitant volume and fraction were also calculated. Results: The table summarizes the pre-sized and post-sized results (mean (SD), along with the p-values of a paired t-test. MR grade is included for completeness.

CONCLUSIONS: The Coapsys device significantly reduced MR acutely. Further study will be required to assess the chronic stability of the repair in this animal model.

OBSERVATIONS:	Pre-Sizing Value	Post-Sizing Value	p-value
MR Grade	3.1 ± 0.7	0.6 ± 0.7	<0.001
EROA (cm ²) (n=7)	0.07 ± 0.03	0.01 ± 0.01	0.003
MR area (cm ²)	3.4 ± 1.2	0.9 ± 0.4	<0.001
MR/LA area	0.31 ± 0.08	0.09 ± 0.04	<0.001
Regurgitant Volume (ml) (n=7)	8.3 ± 4.4	2.4 ± 2.1	0.014
Regurgitant Fraction (%) (n=7)	39.3 ± 12.2	17.3 ± 13.2	0.010

ABSTRACT 51

EFFECTS OF ELASTIC VENTRICULAR RESTRAINT ON CARDIAC REMODELING IN EXPERIMENTAL HEART FAILURE

James Magovern, Walter McGregor, Dennis Trumble, and Sunil Mankad.
Allegheny General Hospital, Pittsburgh, PA, USA

BACKGROUND: This study evaluates the effects of an elastic restraint device made from nitinol mesh on ventricular function in a heart failure model.

METHODS: Heart failure was induced in 12 mongrel dogs by rapid ventricular pacing for 4 weeks. Echocardiography, right heart catheterization, and pressure-volume analysis were done after pacing to establish a heart failure baseline. The device was placed in 6 animals and the other 6 served as controls. Rapid pacing was continued for an additional 4 weeks, at which point final studies were done.

RESULTS: Comparison of baseline and final studies showed significant advantages in the device group. Indexed ventricular volumes were lower (LVEDVi = 2.06 ± 0.3 vs. 2.57 ± 0.47 mL/Kg, $p=0.04$; LVESVi = 1.50 ± 0.27 vs. 2.03 ± 0.39 mL/Kg, $p=0.02$), central venous pressure was lower (4.3 ± 1.2 vs. 8.1 ± 3.1 mmHg, $p=0.02$), and ventricular elastance was more preserved in the device group ($E_{max} = 5.5 \pm 3.0$ vs. 1.7 ± 1.0 , $p=0.02$). Indices of diastolic function were similar between groups.

CONCLUSIONS: An elastic nitinol restraint device prevented the progression of pacing induced heart failure without producing diastolic dysfunction.

THURSDAY
AFTERNOON

ABSTRACT 52

NEW INTRACARDIAC IMPLANTABLE MINI ASSIST DEVICE PROVIDES SIGNIFICANTLY EFFECTIVE VENTRICULAR UNLOADING

Koen Reesink; University Hospital Maastricht, Maastricht, Limburg, Netherlands

INTRODUCTION: We tested a new, implantable intracardiac mini pump (IP) which was introduced clinically recently. This catheter-based assist device features a 6.4 mm diameter integrated cannula-pump assembly with a capacity of 4.5 l/min for use in trans-aortic valve position. Introduction is either percutaneously or intraoperatively. The efficacy of the IP had yet to be established. We compared the IP with the standard in minimally invasive support: Intra-aortic balloon pumping (IABP).

METHODS: Reversible acute mitral insufficiency (AMI) was created in calves (n = 7) by stenting the mitral valve using a vena cava filter. In each animal maximum IP assist was compared with standard 1:1 IABP assist. Results: Both assist systems (IP/IABP) improved cardiac output (25%/4%), diastolic coronary flow (26%/96%), aortic pressure (17%/11%) and carotid flow (47%/8%). Left atrial pressure was reduced (-2.4/-0.7 mmHg) as well as left ventricular work (-46%/-4%). All significant (p<0.05).

CONCLUSION: The IP unloads the left heart more effectively than IABP. However, IABP favored coronary perfusion more. The IP may be a viable mechanical support alternative in case of acute ventricular failure to existing systems like the IABP and extracorporeal life support.

ABSTRACT 53

IMPROVED SURVIVAL IN CARDIogenic SHOCK AFTER MYOCARDIAL INFARCTION WITH VENTRICULAR ASSIST DEVICE (VAD) SUPPORT.

John W. C. Entwistle III M.D., Ph.D., Paul B. Bolno M.D., Elena Holmes N.P., Louis E. Samuels M.D.

Cardiogenic shock after acute myocardial infarction is associated with a very high mortality rate. To improve survival in these patients, we have provided mechanical cardiac support using the Abiomed BVS 5000 to 15 patients (average age 58.5 years) in cardiogenic shock after myocardial infarction who were failing medical management, and in whom death appeared to be imminent. Ten patients were suffering primarily from left ventricular dysfunction and were supported with a left ventricular assist device (LVAD). Eight of these patients were weaned from device support, and 6 survived. In contrast, 5 patients presented with bi-ventricular failure or combined pulmonary and left ventricular failure, and were supported with bi-ventricular VADs (BiVAD) (n=4) or an LVAD with extracorporeal membrane oxygenation (ECMO) (n=1). None of these patients could be weaned from device support. Two BiVAD patients underwent cardiac transplantation, and only one survived.

Thus, in the presence of left ventricular failure producing cardiogenic shock after myocardial infarction, LVAD support can produce a 60% survival rate in those patients who are failing medical management. However, in patients requiring bi-ventricular support or ECMO after myocardial infarction, BiVAD support may be used to stabilize the patient until transplantation, but the overall prognosis remains poor.

THURSDAY
AFTERNOON

ABSTRACT 54

SURGICAL TREATMENT OF HEART FAILURE IN PATIENTS WITH PRIMARY AND ISCHEMIC DILATED CARDIOMYOPATHY

N. Radovanovic, Lj. Petrovic, B. Mihajlovic, M. Kovac, Z. Potic, M. Popov, M. Zorc*

University Clinic of Cardiovascular Surgery, Novi Sad, Yugoslavia,

*Institute of Histology, Medical Faculty, Ljubljana, Slovenia

OBJECTIVE: The aim of this study is to show hemodynamic and clinical improvement of heart failure after Reductive Annuloplasty of Double (mitral and tricuspid) Orifices (RADO) in ischemic (IDCM) and primary dilated cardiomyopathy (PDCM).

MATERIAL & METHOD: There were 341 patients, operated due to DCM in the period from November 1986 to July 15, 2002. The group IDCM consisted of 231 pts (68%) with mean ejection fraction (EF) 23.3%. From July 1991, 110 pts from the group PDCM with mean EF 22.9% were operated on.

RESULTS: Postoperative 30-day mortality was 5.9% for the whole group, 7.3% for IDCM and 2.7% for PDCM. Follow up survival was: for IDCM at 5 years $61.5 \pm 4.0\%$ and at 14 years $38.2 \pm 8.0\%$, and for PDCM at 5 years $43.9 \pm 5.6\%$ and at 10 years $21.3 \pm 8.5\%$.

CONCLUSION: RADO corrects remodeling of the fibrous skeleton of the heart, changes spherical geometry of the left ventricle, improves hemodynamic action of the left and right ventricle and slows down progression of heart failure. We recommend RADO procedure as an important associated procedure in IDCM and as a new surgical alternative in the early stage of PDCM, immediately after the first decompensation.

ABSTRACT 55

IMPROVED PATIENT OUTCOMES OBSERVED WHEN TMR IS UTILIZED FOR HYBRID REVASCULARIZATION.

Kurt Wehberg, J. Stephen Julian, James Todd, Nicholas Ogburn, Edward Klopp, Michael Buchness;
Peninsula Regional Medical Center, Salisbury, Maryland

BACKGROUND: Improved outcomes were found when Transmyocardial Revascularization (TMR) was used as an alternative, or as a hybrid technique, to more completely revascularize limited-option patients.

METHODS: 45 patients with mean CCSAS baseline angina score of 3.4 matched our patient selection criteria and were treated with TMR using a Holmium: YAG laser. Inclusion criteria was EF > 30%, no identifiable surgical targets on anterior or lateral wall and/or documented reversible ischemia. Exclusion criteria were unstable angina or recent MI. 36 of these patients received a hybrid CABG/TMR procedure while 9 patients solely received TMR.

RESULTS: Average CCSAS score was 0.9 at 9 months. The TMR group vs. the average CABG patient had 0% mortality vs. 2.12%, 0% bleeding re-op vs. 0.085%, 0% respiratory and renal failure vs. 2.8% & 1.7% respectively, and 0% neurologic complications vs. 1.2%. Length of stay for the TMR/CABG hybrid technique was 7.1 days vs. 8.2 for CABG alone.

CONCLUSION: TMR as an alternative or hybrid revascularization technique is an effective treatment for surgical patients with limited options.

THURSDAY
AFTERNOON

ABSTRACT 56

USE OF CARDIAC RESYNCHRONIZATION THERAPY FOR TREATING HEART FAILURE IN DILATED CARDIOMYOPATHY

Brofman, P., Milani, R., Giffhorn, H., Moutinho, J., Guimarães, M., Pontarolli, R., Maia, F., Silva, M., Barberato, S.
Pontifícia Universidade Católica do Paraná.

INTRODUCTION: For more than a decade, cardiac resynchronization therapy has been suggested as an alternative for treating heart failure in patients with dilated cardiomyopathy resistant to pharmacological therapy. Three different modes of stimulation have been suggested: electrotherapy using dual chamber pacemaker with short atrioventricular interval, atrioventricular pacing or right ventricular bifocal pacing, and atrioventricular or biventricular pacing. After this period, the clinical and functional improvement of patients was evident with the last mode of pacing, in both randomized and nonrandomized studies.

OBJECTIVE: To show the results of 22 patients (60% female) submitted to surgery in the Hospital Universitário Cajuru – PUCPR and Hospital Vita de Curitiba for cardiac resynchronization therapy and evaluated through analysis of functional class (NYHA), maximum oxygen consumption (6 patients), final left ventricular diastolic diameter (LVDD) and left ventricular ejection fraction (LVEF).

RESULTS: In the right atrium and ventricle all leads were implanted through endovascular via. In the LV, 12 leads (Corox LV-P/H, Biotronik) were implanted through coronary sinus (with 3 complications), and 13 through small left thoracotomy by using epimyocardial pacing leads (ELC 54UP, Biotronik) (including the 3 patients who presented complications with the endovascular pacing leads). Three patients had association with replacement of mitral valve due to heart failure secondary to cardiomyopathy—one of them died in the hospital and the other 2 died during the post-operative (one cardiac death and one sudden death). The follow-up period ranged from 1-24 months (m), with an average of 10 ± 5.7 m. The functional class of 3.7 in the pre-operative (PRE) dropped to 2.1 in the post-operative (POS) $p < 0.023$. The maximum oxygen consumption (mL/kg/min) in the PRE changed from 13.1 ± 2.1 to 14.9 ± 1.4 in the POS, $p < 0.043$, the final LV diastolic diameter (mm) in the PRE changed from 72.5 ± 5.7 to 69.4 ± 7.5 in the POS, $p < 0.048$, the ejection fraction in the LV (%) changed from 0.33 ± 0.027 to 0.42 ± 0.072 , $p < 0.018$.

CONCLUSION: After an average follow-up of 10 ± 5.7 m all survivors presented stable improvement in the parameters assessed.

ABSTRACT 57

CARDIAC-COMMITTED STEM CELLS FROM HUMAN UMBILICAL CORD AND BONE MARROW: *in vitro* RESPONSE TO INDUCERS AND FUNCTIONAL CELL CHARACTERIZATION AT THE CLONAL LEVEL.

Silvia Beltrami, Eugenio Cesana, Paolo Vanelli, Carlo Antona, Antonio Zaza, Federico Cicirata, Alberto Clivio.

From the Universities of Milano, Catania and the Azienda Ospedaliera "L. Sacco"; Milano, Italy

Our aim is to address the problem of *in vitro* differentiation of human umbilical cord (UC) and bone marrow (BM) stem cells into cardiomyocytes at the clonal level. UC is a convenient source of stem cells, and preliminary results in our lab show that UC mesenchymal cells with cardiac potential can be recovered with yields comparable to those obtained from the BM. Moreover, clones of differentially-committed cells have been obtained, some of which are responsive to cardiac-inducing stimuli.

Differentiation was shown to depend on a wide array of soluble factors, activation of cardiac-specific genes, interactions of differentially expressed integrins with the extracellular matrix (ECM), intercellular contacts and anatomical as well as functional integration. Most of these features have not been clearly defined in humans and were addressed in this study, in order to achieve practical outcomes, including the possibility of a safer autologous or histocompatibility-matched stem cell transplantation.

THURSDAY
AFTERNOON

ABSTRACT 58

**HEART CELL THERAPY AND ANGIOGENESIS:
HUMAN MYOBLASTS CARRYING HUMAN VEGF165
FOR REHABILITATION OF INJURED MYOCARDIUM**

1 Ye Lei, 1 Haider Kh H., 2 Ling LH., 1 Lu JT., 3 Law PK.,
1 Eugene SKW.

1. Cardiothoracic Surgery, National University Hospital, Singapore.
2. Department of Cardiology, National University Hospital., Singapore.
3. Cell Transplantation Inc., Science Park-II, Singapore.

INTRODUCTION: HM as carriers of exogenous VEGF165 for localized and transient expression of VEGF to achieve concurrent angiogenesis and myogenesis to restore global myocardial function in a failing heart.

METHODS: HM were transduced with retroviral and adenoviral vectors carrying lac-z and human VEGF165 genes respectively. The cells were characterized for VEGF165 expression by immunostaining, ELISA and RT-PCR. A rodent heart model of cryoinjury was created in rats. The animals were grouped as control (n=12) and cell transplanted (n=16). Ten days later, PBS or 3×10^6 HM carrying VEGF165 and lac-z genes were injected intramyocardially in the infarct. The animals were maintained on cyclosporine (5mg/kg) post cell transplantation. Heart function was assessed by Echocardiography at 6 weeks after cell transplantation.

RESULTS: The donor biopsies yielded >98% desmin positive HM. The transduction HM continued to secrete VEGF165 at least 18 days in vitro, significantly higher (37 ± 3 ng/ml) than the control HM. Histological examination showed the presence of grafted myoblasts expressing lac-z gene in the cardiac tissue at six weeks post transplant. Echocardiographic assessment revealed significant improvement in ejection fraction in cell transplanted animals as compared to the control animals ($p < 0.05$). Immunostaining for vWF VIII showed increased vascular density in low power field, (17.5 ± 1.05) in transplanted animals as compared to control animal group (3.6 ± 0.7 ; $p < 0.01$).

CONCLUSION: We conclude that HM are potential therapeutic transgene carriers for the repair of damaged heart muscle.

ABSTRACT 59

NOVEL IMPLANTATION OF A LEFT VENTRICULAR ASSIST DEVICE WITHOUT CARDIOPULMONARY BYPASS: OFF-PUMP LVAD.

Satoshi Furukawa, MD, Valentino Piacentino III, PhD, Janice Jones, CRNP, Dipin Gupta, MD, Carol A. Fisher, BA, Theresa Hollander, RN, PhD, Arun K. Singhal, MD, PhD, Mahender Macha, MD, James B. McClurken, MD. Temple University Hospital, Philadelphia, PA, U.S.A.

Left ventricular assist devices have become a useful therapy in patients with decompensated congestive heart failure. These devices have been utilized as bridges to transplantation, recovery and "destination". However, insertion of these devices normally requires cardiopulmonary bypass support.

Cardiopulmonary bypass support may exacerbate already present multiple organ dysfunction and right ventricular failure, respectively. We present a surgical technique of a Thoratec Heartmate VE left ventricular assist system insertion performed without cardiopulmonary bypass using a cardiac stabilization device in a patient with severe end-stage heart failure.

THURSDAY
AFTERNOON

Thursday, March 20, 2003

Original Presentations Breakout Session III
Atrial Fibrillation and Arrhythmia Surgery

Abstracts 60 - 69

(Brittany / Champagne Rooms)

THURSDAY
AFTERNOON

ABSTRACT 60

RADIOFREQUENCY MODIFIED MAZE THROUGH A PORT ACCESS APPROACH: MID-TERM RESULTS

Mustafa Guden, Ertan Sagbas, Ilhan Sanisoglu, Mehmet.Ergenoglu, Belhhan Akpinar
KHU, Florence Nightingale Hospital, Istanbul, Turkey

OBJECTIVE: We assessed the feasibility and effectiveness of the irrigated radiofrequency modified Maze procedure (RFMM) through a port access approach during concomittant mitral valve surgery and evaluated early and mid-term results.

MATERIAL AND METHODS: Between February 2001-November 2002 31 patients underwent the combined procedure through a port access approach. Mean age was 52 + 9 years and the mean duration of AF was 20 + 10 months. Concomittant procedures were mitral valve replacement in 19 and valve repair in 12 patients.

RESULTS: Early mortality was 1 (3%). One patient required reoperation for bleeding and one patient required a permanent pace maker for heart block (3%). Freedom from AF was 100% at the end of the operation (71%sinus, 29%pace) Six and 12 months freedom from AF was 88% and 93%respectively. A transthoracic Doppler examination at 12 months revealed that atrial transport function was present in 90% of cases who were in sinus rhythm. At 12 months, the functional capacity had improved from 2.8 + 0.6 to 1.1 + 0.3 (p<0.05).

CONCLUSIONS: The combination of mitral valve surgery and RFMM was safe and effective through this approach; without any procedure related complication. In terms of feasibility, sinus rhythm restoration and overall outcome the results were encouraging and support the use of this combined procedure through a port access approach in selected cases.

ABSTRACT 61

IRRIGATED RADIOFREQUENCY SURGICAL ABLATION TO TREAT ATRIAL FIBRILLATION

Krishna Khargi; University Hospital Bergmannsheil, Bochum, Germany

OBJECTIVE: This prospective study evaluated the safety and effectiveness of the irrigated-cooled-tip radiofrequency ablation (SICTRA).

METHODS: 160 patients with a mean (SD) euroscore of 6.5 (3.0), duration of AF 55.2 months (61), left atrial diameter 50.4 mm (10.4) and 21 patients with paroxysmal AF had a concomitant anti-arrhythmic SICTRA procedure, which was performed with a hand-held, flexible, pen-catheter (20-32 Watt; 200-320 ml/hour irrigation speed), which enabled the surgeon to match the delivered amount of radiofrequency energy to the estimated atrial wall thickness, creating a conduction block without any tissue dehiscence. Formation of yellow-white blistering endocard lesions, induced by oscillating catheter movements, were considered sufficient. Stable catheter-tissue contact was preserved, without pressurizing the atrial wall against adjacent mediastinal structures. Physical examinations, transthoracic echocardiograms, 24-hour Holter ECG's were obtained 3, 6, 12 and 24 months postoperatively.

RESULTS: 38 CABG-, 62 mitral-, 21 aortic-, 39 double valve procedures ± CABG were performed. No oesophageal-, pulmonary orifice- or circumflex artery injuries were observed. Mean (SD) follow-up is 17.3 months (15.2). Cumulative postoperative stable SR rates, excluding paroxysmal AF patients, at 3, 6 and 12 months were 63%, 72% and 74%.

CONCLUSIONS: SICTRA is safe and effective.

THURSDAY
AFTERNOON

ABSTRACT 62

EARLY AND LATE OUTCOME AFTER MICROWAVE ABLATION FOR CHRONIC VALVULAR ATRIAL FIBRILLATION

Marian Zembala, MD, Radoslaw Lenarczyk, MD, Zbigniew Kalarus, MD, Dariusz Puszczewicz, MD, Roman Przybylski, MD, Jerzy Pacholewicz, MD
Silesian Center for Heart Disease, Zabrze, Poland

AIM: The aim of the study was to identify clinical parameters, which influence early and late success after surgical microwave ablation (SMWA) for chronic atrial fibrillation (AF) in patients (PTS) undergoing valvular operations.

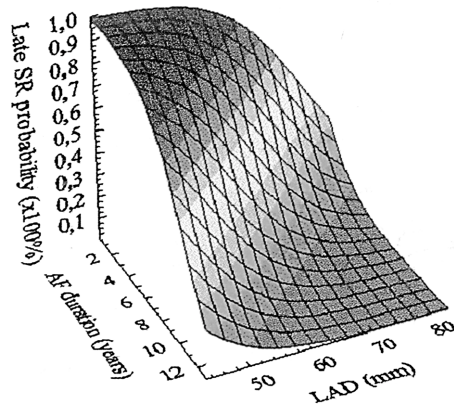
MATERIAL AND METHODS: 42 consecutive PTS underwent mitral valve surgery and simultaneously SMWA for chronic AF. We selected two groups at two time points: PTS remaining on sinus rhythm (SR group) and AF (AF group) at discharge, and PTS demonstrating SR (late SR) and AF (late AF) during mean 7.3 months follow-up. Factors examined included: gender, age, AF duration, left atrial diameter (LAD), type of surgical procedure and surgical order. Presence of stable SR at discharge and incidence of early AF recurrence were additionally evaluated as factors influencing late outcome. Logistic regression was performed to select independent predictors of success.

RESULTS:

	SR (n=32)	AF (n=10)	Late SR (n=28)	Late AF (n=14)
Female	19 (45 %)	7 (70 %)	17 (61 %)	9 (64 %)
Age (y)	55.5	57.4	54.7	58.3
AF Duration (y)	3.6xx	7.4	3.5*	6.5
LAD (mm)	54.9xx	65.4	54.6*	63
Initial 15 cases	11 (34 %)	4 (40 %)	9 (32 %)	6 (43 %)
Mitral + Tricuspid	9 (28 %)	3 (30 %)	8 (29 %)	4 (29 %)
Early AF			15 (54 %)	11 (79 %)
SR at discharge			28 (100 %)**	4 (29 %)

xx 0.001 vs AF, * p<0.05 vs late AF, ** p<0.001 vs late AF

When considering simultaneously, both LAD and AF duration were independent predictors of early and late success.



CONCLUSIONS: LAD and AF duration have the influence on early and late outcome after SMWA. SR at discharge is prognostic for rhythm preservation during follow-up.

ABSTRACT 63

INTRAOPERATIVE MICROWAVE ABLATION IN PATIENTS UNDERGOING VALVULAR SURGERY: MID-TERM RESULTS.

Andrea Venturini, Valeria Cutaia, Angiolino Asta, Domenico Mangino, Roberto Moretti, Elvio Polesel, Alberto Terrini, Claudio Zussa.
Cardiovascular Department, Venice-Mestre, ITALY

PURPOSE: To assess the safety and efficacy of intraoperative microwave ablation to restore sinus rhythm and systolic atrial function in patients undergoing valvular surgery.

MATERIALS AND METHODS: We operated 41 patients with atrial fibrillation (AF). Mean age was 61 years (range: 45-76); AF was permanent in 30 pts and paroxysmal in 11; Associated cardiac procedures were mitral valve repair in 10 pts, mitral valve replacement in 12 and mitro-aortic valve replacement in 19. The microwave procedure (FLEX, AFX Inc.) was performed creating endocardial bilateral, encircling isolation of the ostia of the pulmonary veins.

RESULTS: There was no hospital mortality or morbidity. Mean Follow-up (FU) was 14.2 months. At FU, sinus rhythm was found in 34 patients (83.3%). Echocardiography at FU showed no major or minor left atrial thrombosis and only a mild impairment of the systolic left atrial (LA) function.

CONCLUSION: Intraoperative microwave ablation is a safe and effective treatment to restore sinus rhythm and a mildly impaired LA function in patients with AF undergoing cardiac surgery.

ABSTRACT 64

EPICARDIAL ABLATION USING ARGON CRYO

Eva Berglin, Gunnar Wognsen, Henrik Scherstén, Nils Edvardsson, Birgitta Johansson Departments of Cardiovascular Surgery and Cardiology, Sahlgrenska University Hospital, Gothenburg, Sweden

PURPOSE: Cryosurgery is a well known technique to destroy myocardial conductive properties. The purpose was to investigate whether epicardial cryoisolation of the pulmonary veins (PV) would safely and effectively abolish atrial fibrillation (AF) in patients undergoing CABG and/or valve surgery.

MATERIALS AND METHODS: 40 consecutive patients (32 men), mean age 71 (48-81), with persistent (17) or paroxysmal (25) AF of long (1-31 years) duration, were included. The PV orifices were dissected and epicardial PV isolation was performed using an argon-based cryo system with a malleable, handheld probe producing 7 standardized cryolines around each pair of PV at minus 100-160° C for 60 seconds each. The cryoprocedure was done on bypass, on beating heart, and before other surgical procedures. The mean duration of the cryoprocedure was 18 minutes.

RESULTS: 60% were in sinus rhythm at discharge and 92 % at 3-month follow-up. There were no complications related to the cryoablation.

CONCLUSION: Epicardial cryoisolation of the PV is a safe and simple technique to abolish AF in patients undergoing CABG/valve surgery.

THURSDAY
AFTERNOON

ABSTRACT 65

ELECTROMECHANICAL ASSESSMENT OF LEFT ATRIAL FUNCTION FOLLOWING BEATING HEART ATRIAL ABLATION

Gianluca Bonanomi, David Schwartzman, Marco Zenati
Division of Cardiothoracic Surgery, Atrial Arrhythmia Center, University of Pittsburgh, Pittsburgh, PA, USA

AIM: Current data suggest that left atrial (LA) ablation can cure atrial fibrillation. The aim of the study was to investigate the feasibility, safety and electromechanical consequences of beating heart left atrial ablation using a bipolar radiofrequency (RF) device.

METHODS: Five healthy adult pigs (35-50 kg) underwent a median sternotomy and off pump LA ablation using a bipolar RF device (Atricure Inc.). LA electromechanical properties were studied prior to and after ablation using percutaneous endocardial catheter mapping (NOGA™, Biosense-Webster) and intracardiac echocardiography (AcuNav™, Acuson). Translesion conduction was assessed and pathologic analysis performed.

RESULTS: A lesion pattern recapitulating the LA component of the Maze III procedure was safely delivered. All lesions produced conduction block and resulted to be uniform and transmural with no evidence of charring or barotrauma. Although a significant portion of electrically isolated (EI) atrial tissue was created, the ablation procedure was not associated with significant alterations in global LA conduction time (CT) and mechanics, pulmonary veins anatomy and flow (PVF), and in mitral valve flow (MVF) or left ventricular ejection fraction (EF). There was no evidence of intraatrial thrombus or pulmonary vein stenosis. Results are summarized in the table.

CONCLUSION: The bipolar device enabled the deployment of LA lesions in the beating heart avoiding atriotomies and without adverse effects on LA electromechanics.

Parameter	Preablation	Postablation	p value
EI (%)	13.7±3.4	7.75±9.5	<0.01
LACT (sec)	56.7±6.8	68.5±11	0.2
LAEF (%)	0.22±0.03	0.18±0.03	0.15
LVEF (%)	46.75±8.8	50.75±6.1	0.4
PVF (m/s)	0.97±0.3	1.05±0.2	0.5
MVF (m/s)	2.27±0.3	2.35±0.2	0.4

ABSTRACT 66

IRRIGATED RADIOFREQUENCY ABLATION, TO SURGICALLY TREAT CHRONIC ATRIAL FIBRILLATION : LEFT ATRIAL VERSUS BIATRIAL LESION PATTERN

K. Khargi, Th. Deneke, K-M. Mueller, B. Lemke, A. Laczkovics
Cardiothoracic Surgery, Cardiology, Pathology
University Hospital Bergmannsheil, Bochum, Germany

AIM: The effectiveness of the left atrial ablation, using irrigated radiofrequency ablation (SICTRA), was compared with the bi-atrial procedure in patients with chronic atrial fibrillation (AF).

METHODS: 139 patients, with chronic AF had a SICTRA procedure; 61 a left atrial pattern (Group A) and 78 a bi-atrial pattern (group B).

RESULTS : The mean (SD) age, left atrial diameter, preoperative duration of atrial fibrillation (AF), and Euroscore for group A and B were 68.2 (9.5) versus 66.6 (8.6) years, 51 (12) versus 51 (8.6) millimeters, 58 (64) versus 60 (66) months, 7.3 (3.5) versus 6.0 (2.2) euroscore. The aortic cross clamp time was 99 (21) versus 101 (21) minutes. Mean follow up was 15.2 (11.7) versus 21.8 (17.6) months. The cumulative SR rate at 6 and 12 months for group A and B are 60 % versus 67% and 73 % versus 75 %.

CONCLUSION: The left atrial ablation appeared to be an acceptable surgical alternative to the bi-atrial procedure in patients with chronic AF.

THURSDAY
AFTERNOON

ABSTRACT 67

EPIMYOCARDIAL VERSUS ENDOVASCULAR PACING LEADS IN THE LEFT VENTRICULAR PACING IN THE CARDIAC RESYNCHRONIZATION THERAPY: SURGERY EXPERIENCE

Brofman, P., Milani, R., Giffhorn, H., Moutinho, J., Guimarães, M., Pontarolli, R., Moura Jorge, J., Nadalin, E.
Pontifícia Universidade Católica do Paraná

AIM: To show the study and results of epimyocardial and endovascular pacing leads for left ventricular pacing in 22 patients submitted to surgery in the Hospital Universitário Cajuru da Pontifícia Universidade Católica do Paraná and Hospital Vita de Curitiba, between August 2000 and July 2002.

RESULTS: Twelve patients received endovascular pacing leads (Corox LV-P/H, Biotronik) and 13 patients received epimyocardial leads (ELC 54 UP, Biotronik). The average time for implanting the endovascular lead was 166 ± 55.2 minutes and the success rate of the implantation was 66.6%, and the average time for implanting the epimyocardial lead was 48 ± 8.3 minutes ($p < 0.003$) and the success rate of the implantation was 100% ($p < 0.001$). Right atrial leads were used in 20 patients (the 2 others presented chronical AF). The acute thresholds of endovascular leads ranged from 0.20 to 0.55 mV with an average of 0.34 ± 0.07 mV, the width of the R-wave ranged from 14 V to 31 V with an average of 23.5 ± 4.0 V, and the impedance ranged from 619 to 920 W. In the epimyocardial leads the acute thresholds ranged from 0.4 to 1.8 V with an average of 0.73 ± 0.4 V ($p < 0.02$), the width of R-wave ranged from 9.0 to 27.0 mV with an average of 18.1 ± 4.5 mV ($p < 0.002$), and the impedance ranged from 614 to 886 W with an average of 713 ± 68 W ($p < 0.024$). Three endovascular leads had complications (25%)—one because of infection (8.3%), one because of dislocation (8.3%) and the other for threshold raise. Two of the epimyocardial leads presented loss of command (15.2%) and one of them needed repositioning (7.6%). The average time of progression of the patients ranged from 1 to 24 months with an average of 10 ± 5.7 months. During hospitalization and follow-up, three patients died (13.6%).

CONCLUSION: In this study, the epimyocardial leads were easier to implant and had lower incidence of complications in the post-operative follow-up in this group of patients.

ABSTRACT 68

TOTALLY ENDOSCOPIC TECHNIQUE FOR OFF-PUMP EPICARDIAL ABLATION OF ATRIAL FIBRILLATION ON BEATING-HEART.

Adam Saltman, MD, PhD, Division of Cardiothoracic Surgery, University of Mass. Memorial Medical Center

INTRODUCTION: We report in this abstract the feasibility of a totally endoscopic technique to treat atrial fibrillation (AF). A surgical microwave ablation procedure was performed on a 74-year-old female patient with paroxysmal AF.

METHODS: Three ports were created both into the right and left pleural spaces. After opening the pericardial sac on the right side, the superior and inferior vena cava were dissected free, as was the inter-atrial groove. The Flex 10 (AFx Inc., Fremont, CA) was passed completely around the four PVs. The location and orientation of Flex 10 was confirmed posterior to the LA appendage. The ablation procedure was performed by sequentially heating adjacent 2-cm ablation sections until the pulmonary veins were isolated. A total of 8 sections were activated, for an overall ablation time of 12 minutes. The LA appendage was then removed using an EndoGIA stapler. Hemostasis was immediate.

RESULTS: The patient was in normal sinus rhythm after the procedure.

CONCLUSION: Totally endoscopic off-pump epicardial AF microwave ablation procedures are safe and technically feasible. This report demonstrates the first step toward performing a completely endoscopic ablation pattern similar to the original maze for patient with chronic AF with the FLEX 10 device.

THURSDAY
AFTERNOON

ABSTRACT 69

SURGICAL TREATMENT OF CHRONICAL ATRIAL FIBRILLATION WITH RADIOFREQUENCY ABLATION DURING MITRAL VALVE REPAIR

Friedrich-Christian Riess, Hanns-York Helmold, Ralf Bader, Lorenz Hansen, Stephan Winkel, Niels Bleese; Albertinen Hospital, Hamburg, Germany

OBJECTIVE: With respect to the result the surgical Maze is the gold standard for treatment of atrial fibrillation (AF). However, this procedure is invasive and time consuming. We present our surgical approach of left atrial ablation during concomitant cardiac surgery using radiofrequency (RF).

MATERIAL AND METHODS: The video shows a mitral valve repair with partial resection of the posterior leaflet and annuloplasty. Chronical AF is treated by a modified Maze procedure consisting of a standard left atrial endocardial ablation using a Saline Irrigated Tip Radiofrequency Ablation (SITRA) (Cardioblate, Medtronic, Minneapolis, MN, USA). A sponge behind the left atrium protects structures of the posterior mediastinum. While performing the ablation line between the left pulmonary veins and the mitral annulus, cold modified blood cardioplegia is administered in order to prevent damage to the circumflex artery. Between: 7/2001 and 12/2002 a total of 34 patients (21 male/13 female), mean age 64.2 ± 9.5 years (32 to 82 years) suffering from chronic AF and additional cardiac diseases were treated with SITRA by five different surgeons.

RESULTS: All operations were performed without complications. Until now in 26 (77%) patients the 6-months follow-up was carried out. 15 patients (57.7%) are in stable sinus rhythm, while the remaining 11 (42.3%) patients demonstrate AF.

CONCLUSIONS: Left atrial SITRA using the Cardioblate device offers a safe and easily to perform surgical method for the treatment of chronic AF. We expect the results to improve with growing case numbers.

Thursday, March 20, 2003

Scientific Session III
Surgical Approaches for Left Ventricular Failure

Abstracts 70 - 72

(Grand Ballroom)

THURSDAY
AFTERNOON

ABSTRACT 70

LINEAR SEPTO-ANTERIOR WALL SUTURE AND SEPTO-ANTERIOR WALL-APICAL PATCH FOR EXCLUSION OF ANTEROSEPTAL SCAR

A.M. Calafiore

BACKGROUND: After left anterior descending artery occlusion septal involvement is often higher than anterior free wall involvement. A technique is described that allow to exclude anteroseptal scar recovering a conical shaped cavity without reducing its longitudinal length. The technique is the following:

- A) Some interrupted sutures (generally 2) are used to join the scarred septum in its higher portion to the anterior wall. Sutures stop at the level of the papillary muscles.
- B) Four stitches are placed in the septum (where the sutures end), in the new apex (maintaining obliquity), deep in the septum (at the border between scar and healthy muscle) and in the anterior wall (again at the border of the scar).
- C) An oval patch is tailored (generally 60x30mm) and sutured among the septum, the anterior wall and the new apex, following the 4 stitched previously placed. It will represent the new distal akinetic septum.

MATERIAL AND METHODS: From January to December 2002, 22 consecutive patients underwent anteroseptal scar exclusion using the technique previously described. Mean NYHA Class was 2.7; 10 had mitral regurgitation and underwent mitral valve overreducing annuloplasty. Echocardiographic volumes (ml/m²) were 119 (end diastolic, ED) and 76 (end systolic, ES), with a mean ejection fraction (EF) of 38%. Seven patients had an EF≤35%, with 165 ED and 118 ES and EF 29%.

RESULTS: No patients died and only one had a major complication (acute renal failure). After a mean follow up of 4 months (1-12), volumes changed from 119 to 81 (ED), $p<.001$, and from 76 to 49 (ES), $p=.002$, with EF from 38% to 40%, $p=ns$. Longitudinal length remained unchanged and sphericity index lowered from 0.60 to 0.52, $p<.001$. In patients with EF≤35%, volumes changed from 165 to 98 (ED), $p<.001$, 118 to 68 (ES), $p<.001$, EF from 29% to 44%, $p<.001$. Longitudinal length remained unchanged and sphericity index lowered from 0.62 to 0.55 $p<.001$.

CONCLUSIONS: The technique by us described allows to treat all the dyskinetic or akinetic areas following LAD occlusion when the septal involvement is higher than anterior free wall with good clinical and morphological results.

ABSTRACT 71

COMPLETE HEALING AND LONG-TERM PATENCY OF A VASCULAR ANASTOMOSIS CREATED WITHOUT INTIMAL APPPOSITION USING A NOVEL DEVICE AND CATHETER-BASED DELIVERY SYSTEM

Mitchell J Magee, Michael J Mack, Cardiopulmonary Research Science and Technology Institute, Rodney White, UCLA, Hani Shennib, McGill University, Gita Barry, Jodi J Akin, Vasconnect, Inc.

OBJECTIVE: Vascular anastomosis is achieved by approximation of target and graft vessels with suture, clips or metallic couplers. A novel concept of approximation by passive sealing has been developed. The anastomosis is constructed using pliable non-metal flanges connected by a flow channel. The one-piece device enables physiologic blood flow and vessel wall compliance to form the seal. The study purpose is to evaluate feasibility, healing, and long-term patency.

METHODS: Fourteen vascular anastomoses were performed with a Vasconnect device delivered either by surgical technique (n=6) or via a proprietary catheter delivery system (n=8) in 12 animals (6 sheep, 6 swine). In 8 animals, a standard sutured anastomosis was also constructed with 5-0 or 6-0 polypropylene suture to serve as concurrent controls for comparison of same-phase healing and patency. Anti-platelet therapy with aspirin and either ticlopidine or clopidogrel was given throughout the survival period. Animals were evaluated multiple times in the survival periods for sealing, stability?

THURSDAY
AFTERNOON

ABSTRACT 72

LESS INVASIVE REPAIR OF FUNCTIONAL MITRAL REGURGITATION USING THE MYOCOR COAPSYS: A CLINICAL DEMONSTRATION.

N. Trehan 1, A. Tschircov 2, Y. Mishra 1, D. Nikolov 2, R. Iliev 2, S. Mittal 1, S. Gadeva 2

1. Escort Heart Institute and Research Center, New Delhi, India.
2. University Hospital, "St. Ekaterina", Sophia, Bulgaria

OBJECTIVES: Functional mitral regurgitation (MR) results from dilatation of the mitral valve annulus and / or lateral papillary muscle displacement in dysfunctional left ventricles. The Myocor (Coapsys) device restores leaflet apposition and valve competency off pump without atriotomy. It is currently being investigated in patients with functional MR undergoing concomitant coronary artery bypass grafting (CABG). This video demonstration shows the site identification, implantation and echo evaluation steps for the Coapsys device in a patient with functional MR.

METHODS: The Coapsys device is surgically implanted in patients with functional MR of grade 2 or greater. The Coapsys consists of anterior and posterior epicardial pads connected by a sub-valvular chord. The posterior pad is positioned at the annular level and centered relative to the posterior leaflet. The sub-valvular chord bisects the valve perpendicular to the coaptation line. The Coapsys is sized by reducing the device dimension, drawing the posterior leaflet and annulus toward the anterior leaflet. During sizing, MR grade is assessed in real-time using color flow Doppler echocardiography. Final device sizing is selected when MR is minimized or eliminated.

RESULTS: As demonstrated, the Coapsys device can be safely and easily implanted off pump without atriotomy. Additionally, it can be readily used as an adjunct to procedures such as CABG.

CONCLUSIONS: The Coapsys device shows promise as a less invasive method of repair for patients with functional mitral regurgitation. Clinical evaluations are currently underway to assess the acute efficacy and chronic stability of the repair.

Thursday, March 20, 2003

Mini-Oral Presentations Session II
Coronary Revascularization: Technique and Results

Abstracts 73 - 82

(Grand Ballroom)

THURSDAY
AFTERNOON

ABSTRACT 73

MIDTERM RESULTS OF ROUTINE BILATERAL INTERNAL THORACIC ARTERY GRAFTING

Amir Kramer, MD, oren Lev-Ran, MD, Dmitry Pevni, MD, Yosef Paz, MD, Chaim Locker, MD, Itzhak Shapira, MD, Rephael Mohr MD
Department of Cardiothoracic Surgery, Tel Aviv Sourasky Medical Center, Tel Aviv, Israel

BACKGROUND : Skeletonized dissection of internal thoracic arteries (ITAs) decreases occurrence of sternal devascularization, thus decreasing risk of postoperative sternal complications. This report evaluates routine use of the skeletonizing technique for bilateral ITA (BITA) grafting.

METHODS : From April 1996-July 1999, 1000 consecutive patients underwent skeletonized BITA grafting. There were 763 males and 237 females; 340 patients were older than 70 and 304 were diabetic.

RESULTS : Operative mortality was 3.4%. Four-year survival (Kaplan-Meier) was 90%. Cox regression analysis revealed increased overall mortality (early and late) in patients with chronic obstructive pulmonary disease (COPD) (RR2.16, 95% 2.27, 95% C.I. 1.2-4.7). Early postoperative morbidity included sternal infection (2.1%), cerebrovascular accident (1.6%) and perioperative myocardial infarction (1%). Multiple regression analysis showed COPD to be an independent predictor of sternal infection (OR 3.66, 95% C.I. 1.24-10, 75). During follow-up, angina returned in 49 patients.

CONCLUSION : Bilateral ITA grafting is associated with satisfactory midterm results. However, we do not recommend its use in patients with COPD.

ABSTRACT 74

ACUTE MYOCARDIAL REVASCULARISATION ON THE BEATING HEART AFTER MYOCARDIAL INFARCTION

H. Sahre, U. Kappert, M. Eller, J. Nicolai, N. Hartmann, V. Gulielmos
Heart Center Dresden University Hospital, Dept. of Cardiac Surgery; Dresden,
Germany

INTRODUCTION: Acute myocardial revascularization after myocardial infarction is associated with high morbidity and mortality. Myocardial revascularization without cardiopulmonary bypass has been prospered as an alternative technique to decrease the operative risk.

METHODS: From 01/2000 to 10/2002, among 582 patients (pts) which underwent OPCAB (off pump coronary artery bypass) surgery, 37 pts (6.4 %, age 67 ± 9 years; LVEF $50 \pm 14\%$) were operated during an ongoing acute myocardial infarction. 27 pts (73%) were admitted to surgery for acute revascularization, 10 pts (27%) received a re-do procedure after conventional CABG and 3 pts (8%) out of the series were operated in cardiogenic shock. All pts received surgery after a mean time of 16 ± 37 hours (min. 1 hour, max. 114 hours).

RESULTS: The mortality rate was 13.5 %. The mean number of grafts per patient was 2.2 ± 1.0 . Five pts (13.5%) received an IABP preoperatively and 4 pts (11%) postoperatively. Twelve pts (32%) had additional inotropic drug support. All perioperative data were recorded and analyzed.

CONCLUSION: The presented results suggest that OPCAB procedures in acute myocardial infarction present more than a reasonable alternative to CPB procedures if patients are not operated in cardiogenic shock.

THURSDAY
AFTERNOON

ABSTRACT 75

INFLUENCE OF Y-GRAFT VERSUS BILATERAL IN SITU GRAFTS ON THE RECOVERY OF MYOCARDIAL PERFUSION RESERVE AFTER CORONARY ARTERY BYPASS USING BILATERAL INTERNAL THORACIC ARTERIES

Chang Hyun Kang, Chun Soo Park, Ki-Bong Kim, Jin Chul Paeng,
Dong Soo Lee

Dept. of Thoracic & Cardiovascular Surgery, Dept. of Nuclear Medicine
Seoul National University Hospital, Seoul, Korea

BACKGROUND: There is a concern that construction of a Y graft may cause inadequate graft flow, compared with bilateral in situ internal thoracic artery (ITA) grafts.

METHODS: Eighty-five patients, who underwent off-pump coronary artery bypass using bilateral ITAs for revascularization of the left coronary system, were studied prospectively. Myocardial SPECT was performed preoperatively and 4.7 ± 2.1 months postoperatively, and the graft patency was verified by postoperative coronary angiographies in all patients. Myocardial perfusion reserve was compared between the patients using bilateral ITAs as a Y graft (group I, n=42) and those using bilateral ITAs as in situ grafts (group II, n=40). The left coronary territory was divided into 16 segments, and a total of 943 segments (484 segments in group I, and 459 segments in group II) which showed decreased stress perfusion value under 70% at basal segments and 80% at other segments were included in this study.

RESULTS: The mean values of preoperative stress perfusion were significantly lower in group II than group I ($63.6 \pm 12.4\%$ for group I and $61.2 \pm 12.7\%$ for group II, respectively, $p < 0.05$). In the postoperative SPECT, the values of stress perfusion were not different between two groups ($68.6 \pm 13.4\%$ in group I and $68.5 \pm 13.6\%$ in group II), with significantly increased stress perfusion compared with the preoperative value ($p < 0.05$).

CONCLUSION: Myocardial revascularization using bilateral ITAs as a Y graft demonstrated a significantly increased stress perfusion after surgery and comparable stress values with bilateral in situ ITA in the postoperative SPECT.

ABSTRACT 76

OPERATIVE TACTICS FOR OFF-PUMP CORONARY RE-DO

Ulrich Hake; Michael Hilker, AA Peivandi, Hellmut Oelert
Klinik für Herz, Thorax- und Gefäßchirurgie, Johannes Gutenberg-Universität
Mainz, Germany

OBJECTIVES: Evaluation of the benefit for OPCAB in selected patients undergoing coronary reoperation.

METHOD: 51 patients presenting for elective or urgent redo coronary were considered to be suitable candidates for OPCAB (total OPCAB - patients - 538). The Euroscore was used to evaluate predicted mortality.

Following re-sternotomy an apical suction device was already used to expose the LAD (Xpose™, Guidant CA). After restoration of blood flow to the anterior-septal myocardium further dissection of the ventricle was performed if necessary with the aid of the Xpose™ that served as a "smooth" retractor and exposition device.

RESULTS: Overall, patients received a mean number of 2.0 grafts per patient (range from 1 - 4). The perioperative course of all patients showed no signs of infarction (Troponin T < 0.5 ng / ml). One patient died following discharge resulting in an observed mortality of 2.2 % compared to a mean predicted mortality of 8.9 % (± 9.3 %).

CONCLUSION: Off-pump surgery is a safe procedure for coronary re-operations. Step-wise restoration of blood flow according to functional relevance is the key to operative success.

THURSDAY
AFTERNOON

ABSTRACT 77

OFF-PUMP REVASCULARIZATION IN THE AWAKE AND SPONTANEOUSLY BREATHING PATIENT - A STEP TOWARDS A MORE 'PHYSIOLOGICAL APPROACH'

Wollert, H.G., Müllejans, B.*, Ansorge, K., and Eckel, L.

Clinic for Thoracic and Cardiovascular Surgery, Clinic for Anaesthesiology and Intensive Care, Heart and Diabetes Center*, Mecklenburg-Vorpommern, Karlsburg, Germany

BACKGROUND : Minimally invasive strategies play an increasing role in coronary revascularization. Maintenance of physiological function of organs is the central point of those concepts. Our strategy of beating heart revascularization in the awake and spontaneously breathing patient includes lung function in this concept.

METHODS : Between 12/2001 and 10/2002, the concept was realized in 28 patients (22 male, 6 female). Perioperative analgesia was achieved using cervical thoracic epidural anaesthesia with sensoric blockade C3 to T6 which allowed a painfree sternotomy and all kinds of manipulations during the procedure. Age ranged from 42 to 74 years (mean under 62 years). In the majority of patients regional myocardial immobilization was achieved by using the x-pose de ice (Guidant). No anaesthesia related complications occurred during hospital stay.

RESULTS : All patients but one could be revascularized without the use of the heart lung machine. 1.5 bypasses per patient were created. Time of operation varied between 90 and 255 minutes (mean under 144 minutes). No myocardial infarction occurred; no catecholamines were used. The bleeding was 320ml on average (60ml-625ml) after 6 hours. All patients left the hospital for rehabilitation.

CONCLUSION : Minimally invasive revascularization in the spontaneously breathing patient has been introduced successfully into clinical practice and has shown the feasibility of the concept. The maintenance of the physiological function of the lung may be an important advantage in patients with impaired lung function and therefore contribute to an improved perioperative outcome.

ABSTRACT 78

EXPAND BENEFITS OF NEW TECHNOLOGICAL ADVANCES IN OFF-PUMP CARDIAC SURGERY WITH QUALITY IMPROVEMENT INITIATIVE

Francis P. Sutter, Goldman SM, Ferdinand FD, Wertan MA, Trace CL.
Lankenau Hospital, Wynnewood, PA USA.

PURPOSE: Improved outcomes with off-pump procedures using an apical suction device mandate pathway / process changes and education.

METHODS: To optimize the benefits and improve results of off-pump coronary artery bypass surgery (OP-CAB) and endoscopic vein harvest; a process improvement team (PIT) was developed. The goal was increased staff / patient involvement through education. New technology, process review and changes in clinical pathways were reviewed monthly. Live interactive telecast OP-CAB and didactic sessions were mandated for each staff member.

RESULTS: PIT team organized May 2001. From May 2001 through 09/30/02, 93% of all isolated primary and redo CAB were performed off pump (N=586). Mean 3.3 grafts / patient with 1.9 mean arterial conduits were completed. STS predicted operative mortality was 3.56%. Our 30 day mortality was 0.55% and stroke rate 0.98%. This data compares strikingly with a mortality consistently > 3% for on-pump CAB done at same institution from 1990 - 09/30/02 (N=6482) and OP-CAB most without apical suction device (N=506) performed prior to PIT. Benefits of OP-CAB using apical suction device require a paradigm shift in post-operative care and treatment.

THURSDAY
AFTERNOON

ABSTRACT 79

**MINIMALLY INVASIVE CORONARY ARTERY SURGERY -
ART AND TECHNOLOGY AT ITS BEST**

Dr. Nitu Mandke, Dr. Ajay Choughule, Dr. Shirish Borker, Dr. Ashok Swarup,
Dr. Alka Mandke
Lilavati Hospital And Research Centre, Mumbai, India.

AIM: This study is done to evaluate the data and emphasize the feasibility of doing more than 90% of coronary bypass surgeries off pump with excellent results.

MATERIAL and METHODS: We started coronary artery surgery in 1995. Between 1st January 1996 and 30th June 2002. 2209 patients underwent offpump coronary artery surgery. Cardiac Stabilizers became available to us from January 2000. We analysed our data from 1st January 2000 till 30th June 2002. Total number of CABGs performed were 1474 out of which 1377 (95.43%) were done off pump. Ninety seven patients those who were done on C P Bypass, 63 of those were intended to be done offpump but had to be converted to C P Bypass due to haemodynamic instability. One hundred and sixty three patients were not suitable for offpump surgery were still done offpump. Four hundred and ninety three out of 1377 patients had composit 'Y' grafts using various conduits. In 1377 patients, 4699 anastomoses were performed (3.41 grafts/patient).

RESULTS: Two patient developed CVA, 5 patients were explored for bleeding and 14 patients died (1.01%). One hundred and sixty seven patients underwent graft angiography before discharge. All arterial grafts were patent either individual or composit (100% patency rate). One individual saphenous vein out of 18 got blocked (94.4% patency rate).

CONCLUSION: This data over last 30 months, suggests that large number of patients can be done offpump with good results. Immediate graft patency rates are excellent.

ABSTRACT 80

INFLUENCE OF INNOVATIVE TECHNIQUES ON MID-TERM RESULTS IN OFF PUMP CORONARY ARTERY BYPASS.

Ioannis Toumpoulis, Constantine Anagnostopoulos, Hani Shennib, Joseph DeRose, Daniel Swistel
St. Luke's-Roosevelt Hospital Center at Columbia University, New York, USA

PURPOSE: There is need for documentation of mid-term OPCAB results.

MATERIALS AND METHODS: 3670 coronary artery bypass patients were risk stratified by EuroSCORE. 52 OPCAB between 1992 and 1997 were compared with 1796 on pump patients (CABG) of similar EuroSCORE. 89 OPCAB between 1998 and 2002 (employing "innovative techniques") were compared with 796 CABG patients. National Death Index assessed mortality and Kaplan-Meier curves were constructed. Arterial grafts, number of anastomoses, complications and length of stay (LOS) were noted.

RESULTS:

	OPCAB 1992-1997	CABG 1992-1997	P-value	OPCAB 1998-2002	CABG 1998-2002	P-value
EuroSCORE	11.5±1.8	11.4±0.3	0.949	13.2±1.5	13.3±0.4	0.946
Complications %	11.5	16.6	0.333	10.1	12.6	0.502
Risk adjusted						
30-day mortality	1.2%	0.7%	0.524	0.5%	0.7%	0.641
LOS	13±1.5	11.7±0.3	0.489	7.2±0.6	9.6±0.3	0.019 *
Kaplan-Meier						
avg survival in months	82.1±0.9	94.5±0.9	0.023 **	47±2	46.4±0.6	0.534

THURSDAY
AFTERNOON

Statistically significant: * t-test, ** log-rank

CONCLUSIONS: The advent of innovative surgery significantly improved LOS and "equalized" survival to five years in OPCAB patients when compared to similar risk "on pump" CABG patients.

ABSTRACT 81

LEFT INTERNAL THORACIC ARTERY (LITA) AS A SOURCE FOR COMPOSITE GRAFT FOR TOTAL ARTERIAL REVASCULARIZATION IN OPCAB

M.J.Jasinski MD, FETCS, S.Wos MD, PhD, M.Kolowca MD P.Olszówka MD, R.Bachowski MD, PhD, K.Widenka MD, M.Deja MD, D.Szurlej MD
2nd Dep. Cardiac Surgery, Medical University of Silesia, Katowice, Poland

AIM: To avoid cerebral vascular accidents (CVA) arterial revascularization with composite graft has been applied for off-pump CABG. Our study is looking at clinical, angiographic and perioperative flow measurement data. Results were compared to control group having free radial artery (RA) or free ITA graft performed.

METHODS: 88 patients were prospectively recruited to the study. There were two groups: 53 patients with composite arterial grafts (composite group) and 35 with free arterial grafts (free group). Mean age at operation were 61,4 + 6,6 vs 57,2 + 9,2, average number of grafts: 2,4 + 0,7 vs 2,6 + 0,8 in composite and free graft groups respectively. 20 preselected patients with intension to perform two grafts to LAD and Cx territories were randomly assigned to either of groups and were followed with Transient Time Flow (TTF) and Pulsatile index (PI) measurements perioperatively and angiographic study postoperatively.

RESULTS: There was no mortality in either of groups. Postoperative complications for overall group included three IABP insertions (3.4%), three conversions to CPB (3.4%), four respiratory complications (4.52%), two wound infections (2.3%).

TTF studies revealed for composite vs free group respectively: LITA flow value of 11,5+8,18 vs 10,28 + 6,04 (p=ns), PI : 3,57 + 1,67 vs 5,98 + 2,36 (p=ns) ; RA flow value 16,5 + 8,34 vs 16,57 + 6,02 (p=ns) with PI 2,5 + 0,78 vs 2,38 + 0,49 (p=ns). Angiographic studies showed patent grafts in both groups.

CONCLUSIONS: Arterial revascularization in Off-pump CABG can be achieved with composite grafts, with satisfactory clinical outcome. Flow parameters detected by Transient Time modification of ultrasound method is showing comparable results between composite and free grafts.

ABSTRACT 82

MYOCARDIAL REVASCULARIZATION USING ARTERIAL T-GRAFT–WHICH CONDUIT SHOULD BE CHOSEN FOR FREE GRAFT?

Calin Vicol 1, Stephan Raab 2, Michael Beyer 2

1. Department of Cardiac Surgery Ludwig Maximilian University Munich Grosshadern Medical Center, Munich, Germany.
2. 2Department of Cardiac Surgery, Augsburg Heart Center, Augsburg, Germany.

OBJECTIVES: The T-graft is achieved by the end-to-side implantation of a free arterial graft into the left internal thoracic artery (LITA) left in situ. We analysed our experience in T-grafting to evaluate whether the right internal thoracic artery (RITA) or the radial artery (RA) is better suited as a free graft.

METHODS: Between 1997 and 2001 the RITA was used as a free graft in 129 patients (group I) and RA in 84 (group II).

RESULTS: RITA was more frequently used in male patients ($p < 0.02$) and in patients with a reduced left ventricular ejection fraction ($< 40\%$; $p < 0.03$). Group II patients received more coronary anastomoses (3.7 ± 0.8 versus 3.3 ± 0.8 ; $p < 0.002$). Early mortality (0.8% in group I and 1.2% in group II) and morbidity was comparable. Blood loss however was significantly higher in group I (858 ± 500 ml) than in group II (731 ± 380 ml; $p < 0.05$). During a mean follow-up time of 25.1 ± 1.3 months no significant differences regarding late mortality (5.4% in group I and 0% in group II) and the recurrence of angina (group I: 2.7% vs. 1.4% in group II) occurred. Angiography was performed in 20 symptomatic patients showing a patency rate of all peripheral anastomoses of 90.9% in group I and of 91.3% in group II.

CONCLUSIONS: Based on our experience we recommend to use the RITA as a free graft in tall men also in cases of reduced left ventricular ejection fraction, diabetes and obesity. RA should be used in petite women, if there is a high risk of bleeding and if it is necessary to perform multiple grafting.

THURSDAY
AFTERNOON

Friday, March 21, 2003

Original Presentations Breakout Session IV
Coronary Revascularization: Improving Outcomes

Abstracts 83 - 90

(Grand Ballroom East)

FRIDAY
AFTERNOON

ABSTRACT 83

**MIDCAB VERSUS OPCAB FOR ONE VESSEL DISEASE:
MID-TERM RESULTS**

Calin Vicol, Georg Nollert, Helmut Mair, Vicky Samuel, Bruno Reichart
Department of Cardiac Surgery Ludwig Maximilian University Munich
Grosshadern Medical Center, Munich, Germany

OBJECTIVES: Off-pump cardiac surgery is becoming an established method of surgical revascularization. However, performing anastomoses on the beating heart may be challenging especially through small incisions. We compared our mid-term results in patients with one-vessel disease using full sternotomy (OPCAB) or minimal invasive incisions (MIDCAB).

METHODS: Between December 1996 and December 1998 102 patients (OPCAB=45, MIDCAB=57; age: 61 ± 11 years, 69% male) underwent off-pump myocardial revascularization for left anterior descending artery (LAD) disease with a left internal thoracic artery (LITA) bypass. Patients were selected for OPCAB or MIDCAB technique according to the patients' and surgeons' preference, patient anatomy and risk profile. OPCAB was generally preferred in obese and high risk patients or patients with a large distance between LITA and LAD in a thorax CT. Follow-up consisted of a written questionnaire.

RESULTS: One Patient died in the OPCAB group 3 months postoperatively related to lung cancer. MIDCAB surgery was related to increased creatine kinase levels at 6h postoperatively (95vs.283U/l; $p<0.001$), and a higher incidence of occluded (4vs.0; $p<0.039$) or stenosed (7vs.2; $p<0.06$) bypasses and immediate coronary anigography (9vs.1; $p<0.019$). During follow-up up to 5.2 years MIDCAB patients tended to need more coronary reinterventions (20% vs. 10% at 5 years; $p<0.16$) and develop more recurrent angina ($p<0.12$).

CONCLUSIONS: Small incisions in MIDCAB patients obviously lead to less precise LITA-LAD anastomoses with subsequent higher incidences of myocardial infarctions, reinterventions and recurrent angina. Indication for MIDCAB should therefore be restricted to patients explicitly demanding a small incision despite thorough patient information.

ABSTRACT 84

A PROSPECTIVE STUDY OF THE SAFETY AND EFFICACY OF A COMBINED CLOPIDOGREL AND ASPIRIN REGIMEN FOLLOWING OFF-PUMP CABG

Munemoto Endo, Osama Benhameid, Hani Shennib
The Montreal General Hospital, Montreal, Quebec, Canada

OBJECTIVE: We prospectively evaluated the safety and early efficacy of a combined regimen of clopidogrel and aspirin starting immediately after off-pump CABG.

METHODS: One hundred and thirty-five consecutive off-pump CABG patients received clopidogrel (75mg/day) and aspirin (325mg/day) orally or initially through a nasogastric tube for 3 months commencing within 6 hours of surgery. Additionally, heparin (10000 IU/day) was given subcutaneously during the first 4 postoperative days. Clinical events including death, myocardial infarction (MI), reintervention, angiographically documented graft occlusion, stroke, pulmonary embolism (PE), deep vein thrombosis (DVT) and hemorrhagic events were recorded. All patients were followed up to 3 months.

RESULTS: Thirteen patients among 135 off-pump CABG patients had treatment discontinued prior to discharge due to: refractory atrial fibrillation requiring coumadin (6 patients); gastrointestinal bleeding (1 patient); DVT (1 patient); PE (1 patient) and death (4 patients). All remaining patients were followed up to 3 months. At 1 month, the following events were noted: cerebrovascular accidents 3.0% (3 strokes and 1 transient ischemic attack), MI 3.0%, DVT 0.7% and hemothorax 0.7%. At 3 months, no additional events had occurred except for 1 patient who developed DVT and 2 additional patients who developed MI. Coronary angiography was indicated in these 2 patients. All grafts were found to be patent. However, in 1 patient, a native vessel required percutaneous intervention (stenting).

CONCLUSIONS: Early administration of a combined regimen of clopidogrel and aspirin following off-pump CABG is safe and is associated with a relatively low incidence of MACE, bleeding, PE and DVT. Consequently, its routine administration post off-pump CABG is recommended.

FRIDAY
AFTERNOON

ABSTRACT 85

OFF-PUMP TOTAL ARTERIAL REVASCLARIZATION IN MULTI-VESSEL DISEASE: MYTH OR REALITY?

Ki-Bong Kim, Chang Hyun Kang, Woo-Ik Chang

Department of Thoracic and Cardiovascular Surgery, Seoul National University Hospital, Seoul, Korea

BACKGROUND: The aim of this study was to demonstrate the feasibility of off-pump coronary artery bypass (OPCAB) using exclusively arterial grafts in multi-vessel disease.

METHODS: We prospectively analyzed 238 patients who underwent total arterial OPCAB using two or more arterial grafts (group I), and compared with 87 patients who underwent OPCAB using single arterial conduit and additional saphenous vein grafts (SVG) (group II).

RESULTS: The average number of distal anastomosis was 3.2 ± 0.9 and 3.5 ± 0.8 in groups I and II, respectively ($p=0.005$). Operative mortalities were 0.8% (2/238) and 1.1% (1/87) in groups I and II, respectively ($p=ns$). There were no differences in postoperative morbidities such as atrial fibrillation (11.8% vs. 13.8%), perioperative myocardial infarction (2.1% vs. 4.6%), stroke (0% vs. 1.1%), and mediastinitis (0.8% vs. 1.1%), between groups I and II ($p=ns$). In group I, arterial grafts used were left internal thoracic artery (ITA) in 234 patients, right ITA in 227 patients, right gastroepiploic artery in 116 patients, and radial artery in 12 patients. Postoperative angiographies were performed in 235 patients before discharge and demonstrated 98.7% (733/743) graft patency. In group II, arterial grafts used were left ITA in 84 patients, and right ITA in 3 patients. Postoperative angiographies were performed in 80 patients and demonstrated 94.4% (85/90) graft patency for ITA and 85.8% (163/190) for SVG. Although there was no difference in arterial graft patency between two groups, the patency of SVG was significantly lower than those of arterial grafts ($p<0.001$).

CONCLUSION: Off-pump total arterial revascularization is feasible with excellent early patency rates.

ABSTRACT 86

BEATING HEART REVASCULARIZATION WITH PURELY BILATERAL INTERNAL THORACIC ARTERIES FOR TRIPLE VESSEL DISEASE: BASED ON EARLY ANGIOGRAPHIC FINDINGS

Young Tak Lee, MD, Kiick Sung, MD, Kay-Hyun Park, MD, Tae Gook Jun, MD, Pyo Won Park, MD.

Department of Thoracic and Cardiovascular Surgery of Samsung Medical Center, Sungkyunkwan University School of Medicine, Seoul, Korea

BACKGROUND: To know the feasibility of beating heart complete arterial revascularization with purely bilateral internal thoracic arteries (ITAs) for triple vessel disease, early postoperative coronary angiography (CAG) was performed.

MATERIAL AND METHODS: Between March 2001 to November 2002, 84 triple vessel disease patients (aged 61.1 ± 8.6 years) underwent beating heart revascularization with purely both ITAs. Left ventricular ejection fraction ranged from 23 to 78% (mean $48.6 \pm 19.2\%$). The incidence of diabetes mellitus was 45.2%. Since May 2002, early postoperative CAG follow-up has been performed in 42 patients.

RESULTS: There was no operative death. Perioperative myocardial infarction and postoperative low cardiac output occurred in one patient (1.2%) respectively. The mean number of distal anastomoses was 4.0 ± 0.8 per patient. The patency rates were 100% for the left ITA and 98.3% for the right ITA. Competitive flow patterns were present in 20 distal anastomoses sites (11.8%). Degree of stenosis ($<75\%$), extent of stenosis (focal or diffuse) of the native coronary artery, and the measurement of the intraoperative transit-time flow meter ($<10\text{ml}/\text{min}$) were the risk factors for competitive flow in multivariate analysis.

CONCLUSIONS: This surgical strategy is feasible, safe, and yields good early CAG outcomes even in beating heart revascularization. However, competitive flow patterns were relatively prevalent and it may be necessary to evaluate long-term angiographic follow-up and functional study in these patients.

ABSTRACT 87

OFF – PUMP TOTAL ARTERIAL REVASCLARIZATION WITHOUT AORTIC MANIPULATIONS: TECHNICAL ASPECTS AND MID – TERM CLINICAL OUTCOME

S.Prapas, V. Kotsis, A. Sidiropoulos, J. Panagiotopoulos, F. Danou, E. Kouri, P. Stratigi.

INTRODUCTION: The superiority of OPCAB surgery and the favorable results of arterial revascularization have been well established. In addition, avoidance of aortic manipulations offers solutions to patients in high risk of stroke from aortic atherosclerosis or carotid disease. In our practice we routinely combine the above techniques. Aim of the study: To evaluate the applicability of our method and the mid – term clinical results.

MATERIALS AND METHODS: We operated on 637 patients with isolated coronary artery disease between February 2001 and October 2002. Nineteen patients who were selected to be operated on pump and 16 who underwent mini sternotomy excluded from the study. The remaining 602 patients were retrospectively studied. In all of them we intended to apply diversion of bilateral internal mammary artery flow through preconstructed conduits to the diseased coronary circulation in an off – pump fashion. We used the known T, Y and II composite grafts and extension of proximal RIMA with radial artery. The patient population consisted of 528 men and 74 women aged 34 to 92 years, with a Euroscore of 0-3 in 249 pts, 4-7 in 162 pts, 8-9 in 106 pts and >9 in 85 pts. Forty-one cases were reoperations. All the patients were examined 2 weeks, 3 months and 1 year after the operation. Exercise test was performed 10 – 14 months after the operation.

RESULTS: Conversion to CPB was necessary in 11 pts (1.8%) at the first period of 11 months. Aorta non – touch technique was applied in 598/602 pts (99.3%) and total arterial revascularization in 92%. Use of a saphenous vein graft was required in 43 patients because of a positive Allen test. Mortality rate was 6/602 pts (1%). Eight pts suffered a major complication such as reopening for bleeding (3 pts), low cardiac output (2 pts), sternal wound infection (1 pts), perioperative MI (2 pts). The rate of postoperative atrial fibrillation was 15%. During the postoperative period 2 pts had positive exercise test and the angiographies showed total occlusion of grafts to the right coronary system.

CONCLUSIONS: Off – pump total arterial revascularization without aortic manipulations is applicable in a great range of coronary cases, including high – risk patients and reoperations, with excellent mid – term results given that the team is dedicated to the method.

ABSTRACT 88

IS TOTAL ARTERIAL OFF-PUMP CORONARY SURGERY THE BEST STRATEGY IN ELDERLY PATIENTS?

Claudio Muneretto, Gianluigi Bisleri, Alberto Negri, Jacopo Manfredi
Division of Cardiac Surgery, University of Brescia Medical School,
Brescia, Italy

Aim of the study was to evaluate the strategy of choice for myocardial revascularization in the elderly.

We prospectively enrolled 180 consecutive patients aged over 70 years undergoing isolated coronary surgery and assigned them to: Group 1 (total arterial OPCAB), Group 2 (total arterial on-pump CABG), Group 3 (conventional on-pump CABG with LITA on LAD plus saphenous grafts).

The presence of risk factors was higher in the off-pump group (mean Euroscore: G1=8.6 vs G2=6.3 vs G3=6.1). Mean number of anastomoses was similar between the groups (mean: G1=2.9 vs G2=3.1 vs G3=3) while mechanical ventilatory support, ICU stay and post-operative stay were significantly lower in G1 ($p<0.05$). Post-operative complications as atrial fibrillation, bleeding and blood transfusion occurred less frequently in G1 ($p<0.05$). Hospital mortality was 3.3% in G1 and G2 and 5% in G3.

At follow-up (mean: 16 ± 5 months), G1 and G2 showed better results in terms of graft patency and survival free from late events.

Total arterial OPCAB surgery offered improve short term outcome and mid-term results comparable to on-pump arterial surgery but superior to conventional CABG surgery.

FRIDAY
AFTERNOON

ABSTRACT 89

PRIMARY STENTING VERSUS ATRAUMATIC CORONARY ARTERY BYPASS COMPARISON OF TWO METHODS OF REVASCULARIZATION IN SINGLE LEFT ANTERIOR DESCENDING ARTERY STENOSIS

Marek Cisowski, Janusz Drzewiecki*, Andrzej Jaklik*, Agnieszka Drzewiecka-Gerber*, Wojciech Kruczak**, Włodzimierz Morawski, Andrzej Bochenek
First Department of Cardiac Surgery,*First Department of Cardiology,**Department of Cardio-anesthesiology, Medical University of Silesia, Katowice, Poland

BACKGROUND: Percutaneous revascularization is well-accepted method of treatment in a single left anterior descending (LAD) stenosis. It has become the treatment of choice for LAD lesion with the introduction of primary stenting. For the last few years however, the introduction of minimally invasive coronary artery bypass techniques and endoscopic internal thoracic artery (ITA) harvesting - atraumatic coronary artery bypass grafting (ACAB), have risen the question whether ACAB revascularization would be competitive to percutaneous coronary interventions (PCI) in a single LAD stenosis.

METHODS: Group of 102 patients with CCS class II - IV, and angiographically confirmed single critical stenosis of LAD (type A or B), were treated with primary direct stenting, DS-group I, 50 patients, or with ACAB-group II, 52 patients.

RESULTS: All patients in a group I, have reached a very good angiographic and clinical effect. In one-month follow-up 3 patients (6%), and in six-months follow-up 6 patients (12%) developed restenosis of the LAD. In these cases successful repeated-PCI of target vessel was performed. In a group II very good results of cardiac surgeries were observed. In one- and six-months follow-up all patients remained asymptomatic. Critical stenosis of the LITA-LAD anastomosis was angiographically documented in 1 case (1.9%). That particular patient was successfully treated with PCI. Forty eight pts (96%) from group I, and 49 pts (94%) from group II were included in 12 months follow up. In group I, one patient expired (2%), 12 pts had recurrence of angina (25%). One patient (2%) experienced MACE requiring hospitalization. In group II we did not observe such complications.

CONCLUSIONS: Prevalence of cardiac surgery (ACAB) over direct primary stenting in LAD revascularization has been documented along with slightly higher costs of surgical procedure.

ABSTRACT 90

ATRAUMATIC MINIMALLY INVASIVE CORONARY ARTERY BYPASS. A CLINICAL AND ANGIOGRAPHIC FOLLOW-UP

Marek Cisowski, Wojciech Kruczak, Wł Odzimirz Morawski, Agnieszka Drzewiecka-Gerber*, Andrzej Jaklik, Maria Trusz-Gluza, Rajesh Shresta, Andrzej Bochenek

1st Department of Cardiac Surgery, 1st Department of Cardiology, Department of Cardiac Anesthesiology, Medical University of Silesia, Katowice, Poland

BACKGROUND: Atraumatic Coronary Artery Bypass (ACAB) technique consists of endoscopic internal mammary harvesting followed by an atraumatic chest incision through which a direct-vision anastomosis is performed using conventional instruments. ACAB is a challenging quickly developing surgical technique, resulting in a decrease the physical trauma, smaller number of in-hospital complications and better patients outcome.

METHODS: Between June 1998 and February 2002, we performed 247 ACAB procedures (185 patients (pts) with single vessel - LAD disease, and 62 pts multi-vessel disease). In all the cases the endoscopic LITA harvest was employed. The criteria of eligibility to ACAB were: type B or C lesion in proximal part of the LAD, restenosis after percutaneous coronary intervention (PCI) and multi-vessel disease where hybrid coronary revascularization is possible. A total of 200 pts from this group, with anginal symptoms of Canadian Cardiovascular Society (CCS) 2.57 ± 0.7 were included to prospective follow-up study.

RESULTS: Follow-up period was 6 to 44 months (mean 2.5 years). There were one early (due to myocardial infarction) and two late non-cardiogenic deaths. Major adverse coronary events were observed in 6 pts, (3%) and included: myocardial infarction (2 pts, 1%), aggravation of anginal status (4 pts, 2%). An average pts anginal status was CCS I, ECG exercise test was negative in 172 pts (86%), positive in 20 pts (10%). In eight patients (4%) were not able to perform stress test due to skeletal-muscular disorders. 196 patients (98%) stated their quality of life as very good and good. In 157 pts control coronary angiography was performed (78.5%). Patency of grafts was evaluated with use of Fitz-Gibbon scale. Angiographic studies showed patent LITA-LAD graft in 154 pts (98.1%) - only 3 pts (1.9%) had totally occluded grafts (score 0). Coronary artery disease progression was observed in 14 pts (8.9%) who were treated with PCI.

FRIDAY
AFTERNOON

CONCLUSIONS: Excellent long term clinical and angiographic results can be achieved with ACAB technique. The ACAB is the safe and effective method of treatment proximal LAD lesions thus it may be the treatment of choice in patients with a high risk of stent restenosis. We believe that ACAB approach will have a major impact on the management of coronary patient with type B or C lesion of LAD.

Friday, March 21, 2003

Original Presentations Breakout Session V
Endovascular and Congenital Cardiovascular Surgery

Abstracts 91 - 98

(Le Mans Room)

FRIDAY
AFTERNOON

ABSTRACT 91

NEW XENOGRAFT VALVED CONDUIT (CONTEGRA™) FOR RIGHT VENTRICULAR OUTFLOW TRACT RECONSTRUCTION

A. Chatzis, N. Giannopoulos, D. Bobos, G. Kirvassilis, S. Rammos, G. Sarris.
Department of Paediatric and Congenital Heart Surgery, Onassis Cardiac Surgery Centre, Athens, Greece.

INTRODUCTION: The well known flaws of existing valved conduits for reconstruction of the right ventricular outflow tract (RVOT) continue to stimulate research for the elusive "perfect conduit". We describe here our experience with a gluteraldehyde treated bovine jugular vein conduit (Contegra™).

METHODS: From 06/1999 to 02/2002, 15 consecutive patients aged 2 months to 55 years underwent implantation of a Contegra™ conduit. Diagnoses/procedures included: Repair of truncus arteriosus (2), pulmonary atresia (3), severe pulmonary insufficiency after prior tetralogy of Fallot repair (9), and replacement of degenerated valved conduit (1).

RESULTS: No operative death occurred. One patient required early conduit replacement for unexplained valve thrombosis. Early post-operative mean trans-conduit pressure gradient: 7.7 ± 4.9 mmHg. At mean 18.5 ± 6.9 months follow-up, all patients are asymptomatic with no conduit/valve discernable calcification or notable valve incompetence. Mean trans-valvular gradient: 11.1 ± 4.5 mmHg.

CONCLUSION: The Contegra™ valved conduit is well suited for RVOT reconstruction, avoids usage of additional foreign material and remains well functioning during early follow-up. Nonetheless, long-term durability remains to be ascertained.

ABSTRACT 92

A NEW CLIP DEVICE FOR CONSTRUCTION OF VASCULAR INTERRUPTED ANASTOMOSIS IN CONGENITAL CARDIAC SURGERY

Pascal A. Berdat (1), Jean-Pierre Pfammatter (2), Mladen Pavlovic (2), Thierry Carrel (1)

(1) Dept. of Cardiovascular Surgery, (2) Clinic for Pediatric Cardiology, University Hospital, Bern, Switzerland

The U-clips, a new mechanical vascular anastomotic device developed for CABG surgery, allow precise quick construction of any vascular interrupted anastomosis, preserving pulsatility and growth potential.

We report the first use worldwide of U-clips in 10 pediatric patients (mean age 2.4 ± 1.7 years) between July 2001 and July 2002 for coarctation repair (3), bi-directional Glenn shunt (5), Blalock-Taussig Shunt (1) and arterial switch (1). Median operation time was 207 ± 26 (105–365) min, CPB time 83 ± 19 (0–135) min, aortic cross-clamp (AXC) time 40 ± 10 (0–90) min and postoperative length of stay 8 ± 6 (6–61) days. For coarctation repair (2 end-to-end and 1 extended end-to-end anastomosis) U-clip size 50 was used and AXC was 31, 20 and 32 min, respectively. U-clip size 35 was used for the Glenn anastomosis. Device handling, primary hemostasis and patency were excellent and no device-related complication occurred.

During a follow-up time of 11 ± 4.4 months the child with PAIVS and BTS died, all others are doing well. Echocardiographic assessments demonstrate excellent conditions of all anastomoses without growth restriction.

We conclude, that U-clips may be a valuable alternative to conventional suturing in the construction of vascular anastomoses in congenital cardiac surgery.

ABSTRACT 93

POSTOPERATIVE PAIN AND QUALITY OF LIFE IN PATIENTS UNDERGOING ATRIAL SEPTAL DEFECT REPAIR USING MINIMALLY INVASIVE AND ROBOTIC TECHNIQUES

Jeffrey A. Morgan, MD, Karen W. Hollingsworth, BS, Nicholas J. Colletti, BS, Takushi Kohmoto, MD, Mauricio J. Garrido, MD, Aftab R. Kherani, MD, Deon W. Vigilance, MD, Faisal H. Cheema, MD, Eric A. Rose, MD, Craig R. Smith, MD, Mehmet C. Oz, MD, Michael Argenziano, MD
Division of Cardiothoracic Surgery, College of Physicians and Surgeons, Columbia University, New York, New York, USA

BACKGROUND: Although most studies of minimally invasive cardiac surgery have reported morbidity and mortality, few have addressed more subjective outcome measures, such as pain and quality of life (QOL).

METHODS: Over a 15 month period, 17 patients underwent atrial septal defect (ASD) repair by a totally endoscopic robotic (TE-R) approach. These patients were compared to a similar number of patients who underwent repair of their ASD by a mini-thoracotomy (MT) or sternotomy. QOL was assessed on postoperative day 30 by administering the Medical Outcomes Study Short Form Survey (SF-36). QOL endpoints included bodily pain, vitality, mental health, general health, physical function, and social function.

RESULTS: At 30 days, QOL was best for TE-R patients in all 8 categories, most pronounced in bodily pain (BP, $p=0.014$), mental health (MH, $p=0.034$), and vitality (VT, $p=0.036$) (table). Patients undergoing minithoracotomy, however, did not fare better than those undergoing sternotomy.

CONCLUSION: Repair of an ASD can be performed safely and effectively via a totally endoscopic approach. The totally endoscopic robotic approach resulted in the least postoperative pain and best quality of life despite increased cross clamp and bypass times.

	Sternotomy	MT	TE-R	p
Day 30 BP	42 ± 25	52 ± 11	83 ± 25	.014
Day 30 MH	68 ± 28	56 ± 28	93 ± 10	.034
Day 30 VT	58 ± 21	48 ± 19	80 ± 16	.036
BP time (min)	39 ± 10	47 ± 25	171 ± 73	.002
XCl time (min)	14 ± 5	17 ± 16	39 ± 11	.005

ABSTRACT 94

EARLY RESULTS OF THE BOVINE JUGULAR VEIN FOR RIGHT VENTRICULAR OUTFLOW RECONSTRUCTION DURING THE ROSS PROCEDURE.

H Dave 1, A Kadner 1, U Bauersfeld 2, F Berger 2, M Turina 1, R Prêtre 1

1. University Hospital Zurich, Switzerland
2. Childrens Hospital Zurich, Switzerland

STATEMENT OF PURPOSE: To study the early function of bovine jugular vein (BJV) when used for right ventricular outflow tract (RVOT) reconstruction during the Ross Procedure.

MATERIALS AND METHODS: 13 consecutive patients (median age 12 years, range 30 days to 39 years), who underwent a Ross procedure with RVOT reconstruction using a BJV were reviewed. 7 patients had prior balloon or surgical aortic valvotomy. Additional procedures included: Konno procedure (2), mitral valve repair/replacement (2) and reduction-plasty of the ascending aorta (5 pts). The size of the BJV ranged from 12-22 mm (median 20mm). Patients were followed up with periodic echocardiography.

RESULTS: There was no early or late death. None of the patients encountered any significant postop complication. 1 patient had moderate insufficiency of the BJV in peri-operative examination, which regressed to mild on follow-up. Overall, no patient had more than mild insufficiency at 3 months. 6 patients showed mean gradients across BJV ranging from 8-29mm Hg (median 18.5mm Hg).

CONCLUSIONS: BJV to replace the pulmonary valve in the Ross procedure showed excellent function in the early phase. The large size range and easy availability of this valve are particularly attractive.

FRIDAY
AFTERNOON

ABSTRACT 95

CLOSURE OF PATENT DUCTUS ARTERIOSUS BY VIDEO-ASSISTED THORACOSCOPIC SURGERY; MINIMALLY INVASIVE, MAXIMALLY EFFECTIVE: REPORT OF 550 CASES

Mohammad Hassan NEZAFATI , Ali HAMEDANCHI
Imam Reza Hospital, Mashhad University of Medical Sciences, Mashhad, Iran

OBJECTIVE: In the last decade, increasing interest has focused on different applications and various aspects of minimally invasive surgery. To further determine the safety and efficacy of video-assisted thoracoscopic surgical (VATS) closure of Patent Ductus Arteriosus (PDA), we prospectively studied 550 patients treated by this new method.

METHODS: From June 1997 to October 2002, 550 consecutive patients diagnosed as PDA (mean age: 6 years old), were referred to us, all of them met our inclusion criteria eligible for VATS procedure. Recently, we have made some minor alterations in our routine methodology, which will be discussed in more detail later. After complete closure of PDA by two titanium clips the extubated patient leaves the Operating Room without a chest tube.

RESULTS: All the pertaining data were collected and analyzed. There were two cases of chylothorax, which were successfully treated by thoracotomy and ligation of the small lymphatic ducts, after one week of close observation. The procedure was changed to thoracotomy in four adult patients due to inappropriately dilated canal (greater than 9 mm), meanwhile, four additional patients developed transient recurrent laryngeal nerve dysfunction. All cases were re-assessed immediately after the procedure, and followed for more than 5 years by control echocardiography. No significant complication and residual shunt was recorded during the follow-up period. Mean procedure time was about 15 ± 2 minutes. All patients were discharged shortly after the procedure (~20 hours).

CONCLUSIONS: This experience indicates that video-assisted thoracoscopic surgery is superior to other techniques of ductal closure, as well as it is simple, rapid, cost-effective, and more comfortable for the patients, in addition to the cosmetic benefits.

ABSTRACTS 96

**STENT-GRAFT TREATMENT OF THE THORACIC AORTA:
EXPERIENCE OF 55 CASES.**

Burkhardt Zipfel, Friedrich Knollmann, Robert Hammerschmidt, Roland Hetzer
Deutsches Herzzentrum Berlin, Germany

PURPOSE: To evaluate endovascular stent-grafting as a minimally invasive approach to thoracic aortic surgery.

METHODS: Fifty-five patients (47 male and 8 female, aged 17 - 87 years, mean 58 years) underwent endovascular repair with Talent™ stent-grafts for true aneurysms in eight, penetrating atherosclerotic ulcers in 12, type-B dissections in 17, traumatic ruptures in 13, infection in one and suture aneurysm in four cases. Thirty-seven of the operations were emergency procedures.

RESULTS: Hospital mortality was 9.1 % (five patients). Paraplegia occurred in one patient. Four patients required secondary extensions of the stent-graft soon after the procedure; one was converted to open repair after two weeks. At the time of discharge all aneurysms were successfully excluded. At follow-up (1-35 months) all patients are alive and well. In four cases distal endoleaks required graft extensions.

CONCLUSIONS: Endovascular repair of the descending aorta is technically feasible and provides encouraging results considering that 67 % were emergency procedures. The frequent need for graft extensions requires further technical improvements. Close surveillance after stent-grafting is necessary, especially in lengthy aneurysms and in dissections.

FRIDAY
AFTERNOON

ABSTRACT 97

ENDOVASCULAR REPAIR OF THORACIC AORTIC ANEURYSM: RESULTS FROM PHASE I STUDY WITH MEDTRONIC "TALENT" STENT GRAFT

Joseph E. Bavaria, Alberto Pochettino, G. William Moser, Robert C Gorman, Jeffery P. Carpenter, Ronald M. Fairman
University of Pennsylvania, Philadelphia, PA, United States.

BACKGROUND: Endovascular repair of thoracic aortic aneurysms (TAA) is an evolving modality. We report our early experience with the first generation and subsequent re-design of the Talent device.

METHODS: 19 patients (6 male and 13 female) had repair of TAA with the Medtronic "Talent" stent graft from 7/1999 to 11/2002 under an FDA phase I study. The last 9 grafts were re-designed with greater flexibility to improve deployment at the aortic arch. All patients were high risk for open repair. Mean age was 74.8 + 8.4 yr (range 52-83). 2 patients had aortic dissections. 5 patients (26%) required pre-operative subclavian artery transposition to create a suitable distal arch landing zone.

RESULTS: There was one hospital death (5%) at 37 days due to small bowel infarction. There were four late deaths (21%) at 47, 62, 93 and 131 days postop, secondary to aneurysm rupture, CVA, pneumonia and cardiac respectively. Average length of stay was 10.9 + 11 days (range 3-37 days). 4 patients required infrarenal aortic access conduits because of small/tortuous iliacs. 4 patients developed early Type I endoleaks, all requiring repair with stent graft extensions. No ruptures, late endoleaks or stent migrations were noted at one year mean follow-up. Postoperative paraplegia was not observed.

CONCLUSION: In high-risk populations, thoracic stent grafting with the Medtronic "Talent" device is feasible in most descending aortic pathology with acceptable morbidity and mortality. The re-designed "Talent" device is especially useful in the aortic arch, while the proximal and distal bare springs construction allows deployment close to the celiac or arch vessels.

ABSTRACT 98

**THORACIC AORTIC EMERGENCIES :
IMPACT OF ENDOVASCULAR SURGERY**

Iannelli G., Piscione F., Di Tommaso L., Monaco M., Chiariello M.,
Spampinato N.

Department of Cardiac Surgery and Cardiology, University of Naples - Federico II, ITALY

AIM: Conventional surgery of thoracic aortic emergencies (TAE) - fissured thoracic aortic aneurysms (TAA), acute type-B dissection and traumatic rupture of the aorta at the isthmus (TRA) - is associated to an high risk of mortality and morbidity. Endovascular surgery of TAE has been considered as an alternative procedure.

MATERIALS AND METHOD: From March 2001 to July 2002, 15 patients with TAE were admitted at our department and submitted to endovascular surgery : 3 pts for TRA , 4 pts for fissured TAA , 8 pts for acute type-B dissection evolving to rupture. AngioCT scan was diagnostic in all pts.

PROCEDURE: Under general anesthesia, a stented-graft was placed by unilateral femoral arteriotomy. TAA and type-B pts were submitted to a multiple stent-graft procedure - telescope technique - to cover all the descending thoracic aorta. Endoleaks were not present at angiography and delayed CT scan showed a good sealing of the dissection. Hospital stay average was 4 + 1 days and no deaths and major complications were observed. At mean follow-up (7.6 ± 4.2 months) all pts were alive and completely asymptomatic.

CONCLUSION : Endovascular surgery is a safe and quick technique to treat TAE with an encouraging early results

Friday, March 21, 2003

Original Presentations Breakout Session VI
Innovative Anastomotic Devices

Abstracts 99 - 106

(Brittany / Champagne Rooms)

FRIDAY
AFTERNOON

ABSTRACT 99

IMPLANTATION OF AN EPIMYOCARDIAL LEAD FOR BIVENTRICULAR PACING VIA LEFT LATERAL MINITHORACOTOMY

H. Mair, S. Däbritz, S. Schmöckel, B. Reichart
Dept. of Cardiac Surgery, University of Munich, Germany

The video shows the implantation of an epimyocardial steroid lead (Medtronic 4968) on the left ventricle. The lead is placed in the region of the first marginal branch through a 5 cm left lateral mini-thoracotomy. The patient was a 40 years young man with congestive heart failure (dilatative cardiomyopathy, ejection fraction 25%, left bundle branch block of >240 ms, NYHA III). One day prior to surgery the cardiologists tried to implant a transvenous coronary sinus (cs)-lead for 6,5 hours. The implantation of the cs-lead failed because of dissection of the coronary sinus. The dissection caused a pericardial haematoma of 500 ml. The implantation of the left ventricular epimyocardial lead needed 95 minutes. The threshold was excellent (0.3 V/ 0.5 msec). The amplitude of the R-wave was 17,2 mV.

The significant advantages of epimyocardial leads compared to coronary sinus leads are:

1. Nearly 100% target area reached.
2. Better long term thresholds.
3. Shorter operation time.
4. Since April 1999 no epimyocardial lead failed in biventricular pacing.

ABSTRACT 100

**TOTAL ENDOSCOPIC CORONARY ARTERY BYPASS (TECAB).
INITIAL EXPERIENCE WITH TEN PATIENTS**

Sudhir P Srivastava *, Kirit N Patel, Kris Tamirisa, John Challapalli,
Reyna L Barrera, Veronica A Palma, Moui B Ngyuen, Vishwa P Srivastava
Cardiac Surgical Associates of West Texas Odessa, Texas, USA

AIM OF STUDY: Total Endoscopic CABG (TECAB) has been performed in Europe. As part of multicenter trial, author enrolled patients at a single institution to determine the safety and efficacy of performing Total Endoscopic Coronary Artery Bypass (TECAB) using the DaVinci Surgical System.

MATERIAL AND METHODS: From November 4, 2002 to November 23, 2002, ten patients were enrolled in the TECAB study. There were 6 male and 4 female and age range 34-72 years with a mean of 58.3 \pm 14.8 years. The entire procedure was performed through three ports in the 3rd, 5th, and 7th left intercostal spaces. A small oblique incision was made in the groin for femoral artery and vein cannulation and TEE guidance was used for placement. Estech arterial cannula and Heartport venous cannula were used. Antegrade cardioplegia was used to achieve cardiac arrest. LIMA to LAD anastomosis was done using the Coalescent surgical U-clips.

RESULTS: TECAB was successfully completed on all patients. Anastomotic time ranged from 15–30 minutes with a mean of 20.9 \pm 4.79 minutes. Aortic cross clamp time ranged from 39-77 minutes with a mean of 56.10 \pm 12.11 minutes. CPB time ranged from 60-175 minutes with a mean of 89.70 \pm 33.11 minutes. Operative time ranged from 200-368 minutes with a mean of 247 \pm 74 minutes. Extubation time in the ICU ranged from 2.45-29.05 hours with a mean of 10.4 \pm 8.5 hours. The average length of hospital stay was 1-3 days with a mean of 2.0 \pm 0.71 days. There was no mortality, atrial fibrillation, or peri-operative MI. None required conversion or exploration for post-operative bleeding.

FRIDAY
AFTERNOON

ABSTRACT 101

U-CLIP ANASTOMOSES IN CORONARY ARTERY BYPASS GRAFTING – INTIAL CLINICAL EXPERIENCE.

Oz M. Shapira, Rahul V. Pawar, Yusheng Bao, Umer Sayeed-Shah, Harold L. Lazar, Richard J. Shemin
Boston Medical Center, Boston, MA, USA

BACKGROUND: Recent studies suggested that U-clip™ interrupted coronary artery anastomosis is superior to continuous suture. However, clinical experience with this device is limited.

AIM: To evaluate our initial clinical experience with this technology.

METHODS: Outcomes of 41 patients undergoing isolated coronary artery bypass grafting (CABG) using U-clips™ (UC) were compared to 137 patients undergoing CABG using conventional sutures (Conv).

RESULTS: Average number of distal anastomoses were similar between the groups (UC: 3.1, Conv: 3.3, $p=0.3$). Also similar were the number of arterial grafts (1.6 vs. 1.4, $p=0.2$), % of sequential anastomoses (10% vs. 9%, $p=0.9$) and % performed "off-pump" (27% vs. 26%, $p=0.9$). Cardiopulmonary bypass and aortic cross-clamp time were longer in the UC group (97 ± 24 vs. 85 ± 27 min, $p=0.07$; 68 ± 16 vs. 57 ± 19 min, $p=0.03$). Operative mortality (UC: 2.4%, Conv: 1.5%), postoperative MI (0% each), stroke (0% each), renal failure (0% vs. 1.5%), and blood transfusion rate (51% vs. 58%) were not statistically different. Average follow-up in 36 (90%) of UC patients was 5 ± 2 months (range 1-7 months). One patient expired from a non-cardiac-related cause. At the time of follow-up 90% of patients were in angina class I-II.

CONCLUSIONS: The U-clip interrupted anastomosis technique is versatile, safe and associated with excellent short-term outcomes.

ABSTRACT 102

LONG-TERM PATENCY OF VEIN TO CORONARY ANASTOMOSES FOLLOWING PLACEMENT WITH THE C-PORT AUTOMATED ANASTOMOSIS SYSTEM IN A SHEEP MODEL

B. Hausen MD, S. Demertzis MD, L. Hook RVT, I. Ibi MD, P. Demers MD, R. Robbins MD

Dept. Cardiothoracic Surgery, Stanford University, CA, Cardiocentro Ticino, Lugano Switzerland, Cardica Inc., Menlo Park, CA

BACKGROUND: There is a clinical need for a safe and reliable automated vascular anastomosis system to facilitate minimally invasive beating heart coronary bypass procedures. This study was designed to test a novel distal anastomosis system in a chronic CABG model in sheep.

METHODS: Vein conduits were anastomosed proximally to the aorta using either standard hand-sewn techniques (HS) or the PAS-Port proximal anastomosis system. The distal anastomoses were either performed with the staple-based C-Port system (C-Port) or using standard hand-sewn techniques (HS) on the beating heart. The automated device allows the attachment of grafts to coronaries from 1 to 4 mm in diameter while maintaining intracoronary blood flow during placement. Automatically placed micro staples result in a compliant anastomosis. No antiplatelet or anticoagulant drugs were administered during the 9 week follow-up. Final evaluation included a coronary angiogram followed by macroscopic and microscopic assessment of the anastomoses.

RESULTS: A total of 14 animals were included in the study. One animal in the HS group and 2 animals in the C-Port group each deceased intraoperatively due to arrhythmias. The internal diameter of the distal targets in animals that survived the follow-up period was similar in both groups and ranged between 1.0 and 2.5 mm. Graft blood flow was 33.7 ± 21.5 ml/min in the HS group and 21.0 ± 12.8 ml/min in the C-Port group (p n.s.). Four of the 6 HS animals (67%) and 5 of the 5 C-Port animals (100%) showed angiographic patency. At the end of the follow-up a smooth endothelialized inlet into the vein graft with complete healing of the anastomotic site was observed.

CONCLUSIONS: A distal anastomosis of vein to coronary can be safely and rapidly performed with the C-Port anastomosis system using a single tool and by simple actuation of a button. The long-term patency and histology of device anastomoses was excellent. This system enables the surgeon to complete a compliant distal anastomosis virtually within seconds. These results warrant further clinical evaluation.

FRIDAY
AFTERNOON

ABSTRACT 103

EXPERIMENTAL RESULTS WITH AUTOMATED MAGNETIC ANASTOMOSIS DEVICE

J. Zhang, D. Halloway, A. Cheung, A. Sharkawy, S. Drucker, S. Lichtenstein
St. Paul's Hospital, Vancouver, British Columbia, Canada

BACKGROUND: Experimental and clinical outcomes with the Ventrica Magnetic Vascular Positioner (MVP™) have been reported. Angiographic patency, strength of the connection, device ease of use, and hemostasis have been documented. These previous findings have been compiled with a device for vessels with internal diameters equal to or greater than 2.0 mm. We evaluated an iteration of the device suitable for a wider range of vessel diameters.

MATERIALS AND METHODS: Twenty-seven domestic white swine (45-65 kg) underwent coronary artery bypass (CABG) through a left thoracotomy. A left internal thoracic artery (LITA) was attached to the left anterior coronary artery (LAD) with the Ventrica Series 6000 MVP™ anastomotic device. Nineteen animals received the larger size of the device intended for vessels with internal diameters equal to or greater than of 2.0 mm. The remaining eight animals received the smaller size of the device intended for vessels with internal diameters less than 2.0 mm. Angiographic patency was assessed at 30 ± 10 days. Strength of connection, hemostasis and ease of use were also assessed.

RESULTS: Three of the animals with the larger size device were excluded from follow-up for non-device-related reasons. Angiographic patency was demonstrated in 24 of the remaining 24 subjects (100%). There were no leaks in or disruptions of the anastomoses formed with the device. The device was also quick and easy to use.

CONCLUSION: The MVP™ Series 6000 demonstrates functional characteristics at the 30-day interval similar to or better than earlier iterations of the design, while being suitable for a wider range of vessel sizes.

ABSTRACT 104

VETTATH'S ANASTAMOTIC OBTURATOR - A SIMPLE PROXIMAL ANASTAMOTIC DEVICE

Dr. Murali, P. Vettath

Malabar Institut of Medical Sciences; Kozhikode, Kerala, India

BACKGROUND: Proximal anastomosis of a vein graft is usually performed with a side clamp on the aorta. But during beating heart surgery, and when there is only one island of aorta that remains normal, then, applying a side clamp has remained a cause for postoperative neurological events.

MATERIAL AND METHODS: We have fabricated this simple device to perform the proximal anastomosis. This has been used in 78 of our 90 OPCAB'S performed in the last five months in our new center, without any neurological complications.

RESULTS: This obturator is fabricated in different sizes, according to the size of the aortic punch. Once the aortic punch hole is made, the obturator is inserted, and the vein graft is sutured on the aorta, making sure the sutures lie loose. Once suturing is complete, the obturator is removed and the sutures tightened and knotted. Sometimes a purse string is used to prevent bleeding.

DISCUSSION: Using this device we have been able to perform all our proximal anastomosis of the vein grafts on the aorta without dropping the pressures and on calcific aortas.

FRIDAY
AFTERNOON

ABSTRACT 105

EXPERIMENTAL MINIMALLY INVASIVE CORONARY ARTERY BYPASS USING A BIOLOGIC GLUE SHORT AND LONG TERM RESULTS

Steven Gundry, MD

International Heart Institute of Palm Springs, Palm Springs, California, USA

OBJECTIVE: Perfection of minimally invasive coronary artery anastomoses has been frustrated by the complex process of suturing. While distal, metal based anastomotic devices are in development, they offer the same disadvantages of cardiologist's stents that they are designed to compete with. We have previously reported on our early in vivo and in vitro work creating an internal mammary artery to coronary artery anastomosis using a double balloon catheter system and a biologic glue, formed from bovine albumin and glutaraldehyde (BioGlue). This report details the short and long term follow-up of these anastomoses using both stopped and beating heart techniques.

METHODS: Five yearling goats weighing from 41 to 60 kg underwent a single coronary artery bypass from either the left or right IMA to the LAD via a small left anterior thoracotomy. Three initial animals were placed on bypass and had the anastomosis constructed under cardioplegia arrest. Two angioplasty-type balloons were introduced into the distal IMA; one exited the back wall of the IMA 1 cm proximally and entered the anterior wall of the LAD; the other was positioned proximal to the anastomosis to occlude and temporarily stent the LAD. Stay sutures were placed proximally and distally at the anastomosis. Once the balloons were inflated, BioGlue was applied externally and allowed to set-up for two minutes; the balloons were deflated and removed and the distal end of the IMA was clipped, converting the side to side graft to an end to side graft. Following these initial successes, two additional animals had the same procedure using off pump techniques, using a stabilizer to control movement at the anastomotic site. All animals were recovered and followed.

RESULTS: Animals were autopsied at one day, 3 months, 10 months, 12 months, and 27 months. All anastomoses were patent. Angiograms showed patent, non-stenosed, non-aneurysmal graft sites. The 27 month animal (off pump) was allowed to grow from 41 kg to 60 kg prior to sacrifice; despite animal growth, the anastomosis was pristine. BioGlue was still present at 27 months and remained pliable and smooth. This glued anastomosis has subsequently been duplicated in a human cadaver model using robotics and port access.

CONCLUSION: We have shown that a commercially available biologic glue can be used with a catheter system to produce long term patent coronary artery anastomoses in growing large animals. No long term adverse effects of the glue have been found in this model. Further development of this technique could enable robotic or other true minimally invasive anastomoses in cardiac and other fields of surgery.

FRIDAY
AFTERNOON

ABSTRACT 106

NOVEL DISTAL ANASTOMOTIC DEVICE: LONG-TERM PATENCY AND HISTOLOGICAL FINDINGS

Yaron Bar-El 1,2; Fermin O. Tio 3; Rona Shofti, 2.

1. Department of Cardiac surgery Rambam Medical Center
2. Technion, Haifa, Israel,
3. Biomedical Research Foundation of South Texas, Inc. San Antonio, TX.

PURPOSE: Efficacy and long-term patency of the new distal anastomotic device (DAD) for the creation of a rapid, sutureless, end-to-side venous or arterial coronary artery bypass graft anastomoses were tested in a sheep model.

METHODS: In 34 sheep, on beating hearts, the DAD was used to create 20 anastomoses between saphenous veins (n=9) or internal mammary arteries (IMA) (n=11) and various coronary arteries. Fourteen conventional hand sutured anastomoses (veins=7, IMA=7) served as controls. Sheep were sacrificed after one day, one week, and one, three and six months.

RESULTS: Immediate patency of all anastomoses was proved by flow rates and pattern. There was no significant difference between DAD and suture anastomoses in pre-sacrifice Pulsatility-Index and occlusion rate. The histomorphometric studies showed complete intimal bridging over the DAD with no significant difference between DAD and suture anastomoses in respect to lumen diameter mural injury, inflammation or adventitial fibrosis.

CONCLUSIONS: The DAD enables the creation of rapid, efficient, sutureless, venous or arterial coronary anastomoses. Long-term results show that the DAD is comparable to conventional sutured anastomoses.

Saturday, March 22, 2003

Scientific Session VI
Innovative Valve Technology

Abstracts 107 - 114, 181

(Grand Ballroom)

SATURDAY
MORNING

ABSTRACTS 107

EARLY RESULTS WITH A TOTALLY NEW DESIGNED EQUINE PERICARDIAL STENTLESS AORTIC VALVE

Friedrich S. Eckstein, Franz F. Immer, Christian Seiler, Pascal Berdat, Beat Kipfer, Jürg Schmidli, Thierry P. Carrel
University Hospital Berne, Dep. of Cardiovascular Surgery and Cardiology,
Freiburgstrasse, CH-3010 Berne, Switzerland and 3F Therapeutics

OBJECTIVE: The 3F Aortic Bioprosthesis is a new stentless valve (currently under investigation). It has a totally new tubular design and is fabricated from three equal leaflets of equine pericardium. The valve is fixed in the annulus in standard technique either by running or interrupted sutures. There is no need for a second suture line since three commissural tabs only have to be fixed through the aortic wall. Favorable hemodynamics, durability and stress performance were proven during laboratory and animal tests. We present the early clinical results and hemodynamic performance of the 3F valve in patients undergoing aortic valve replacement.

METHODS: Between June and November 2002, 13 patients (7m/6f) underwent AVR with a 3F valve. Mean age was 70.5 ± 16.5 years (range 41-88). In 4 patients combined revascularization was performed, one patient received bi-atrial ablation therapy. Peak systolic gradient (PSG) and valve performance were investigated intra- and postoperatively by Doppler echocardiography.

RESULTS: There was one intraoperative non valve-related death. ECC time was 95 ± 26 min, aortic cross clamp time was 76 ± 20 min. Sizes for implanted 3F valves were: 3x 23mm, 5x 25mm, 4x 27mm and 1x 29mm. Postoperatively 3 patients received warfarine due to intermittent atrial fibrillation, the other patients received anti platelet medication only. No thromboembolic event occurred. At 30 day follow-up PSG was 12 ± 3 mmHg. During the follow-up period trivial central aortic valve regurgitation was found in two patients.

CONCLUSION: Excellent preliminary results with the 3 F aortic valve encourage us to continue the investigation of this prosthesis. Due to the new valve design, implantation technique is simplified comparing with other stentless valves. Long-term evaluation and follow-up is mandatory to assess hemodynamic performance and durability.

ABSTRACT 108

CLINICAL OUTCOMES OF THE FIRST 100 CONSECUTIVE IMPLANTATIONS OF SELF-ASSEMBLED COMPOSITE GRAFTS

Paul Urbanski;

Herz-und Gefäß-Klinik Bad Neustadt, Germany

AIM: The aim of the study was to evaluate the clinical outcome of the first 100 consecutive implantations of our self-assembled composite grafts for replacement of the ascending aorta and aortic valve. The valve prostheses are placed within a Dacron tube leaving a small rim of Dacron underneath the valve for fixation at the aortic annulus.

METHODS: For the composite grafts commercially available biological stentless valves (SPV To-ronto) were used in 53 patients with a mean age of 69.4 years (Group A). In 47 patients with a mean age of 54.1 years (Group B) mechanical valves offering improved hemodynamic performance (St. Jude Regent or ATS AP) were used. The surgical indication was a true aneurysm in 90 and type A aortic dissection in 10 patients.

RESULTS: There was no perioperative (30-day) mortality. Echocardiographic examinations prior to discharge revealed excellent hemodynamic characteristics with low transvalvular gradients in both groups.

There were 4 deaths during the follow-up period (one cardiac and three non cardiac deaths). All of them occurred in the elderly patients Group (A).

CONCLUSIONS: The modified self-assembled composite graft is an excellent alternative to commercially available standard conduits. The use of biological stentless or low profile mechanical valve prostheses in connection with supraannular valve placement improves hemodynamic and hemostatic characteristics. In addition the stentless composite grafts are suitable for those patients, in whom anticoagulation should be avoided.

ABSTRACT 109

EARLY RESULTS ON A SERIES OF 117 PATIENTS OPERATED ON FOR ACUTE TYPE A AORTIC DISSECTION BETWEEN 1992 AND JUNE 2002

Saverio La Francesca, Andrea Antonazzo

Dpt of Cardiovascular Surgery. University of Rome "La Sapienza", Rome, Italy

METHODS: 75 pts. (64%) men and 42 (36%) women aged 28 to 82 years (mean 58.8 + 12 years). Eighteen patients (15.3%) had Marfan syndrome. There were three groups: in group A operations were performed under deep hypothermic circulatory arrest (18 C), in group B patients operated with deep hypothermic circulatory arrest and retrograde cerebral perfusion and group C operated with selective antegrade cerebral perfusion with moderate hypothermic circulatory arrest (28 C).

RESULTS: The overall early mortality (30-day) was 23 % (27 patients) group A: 14 p (25%) group B 7 patients (23%) group C 6 patients (21%). In the last three years early mortality has leveled down to 18%. There was no statistical significant difference in early mortality among the different groups. On univariate analysis the following factors had a significant influence on 30-day mortality: postoperative renal failure (p=0.0051), repeat sternotomy for bleeding (p=0.0096), permanent neurologic deficit (p=0.0059), preoperative low cardiac output (0.0108).

CONCLUSION: Antegrade selective perfusion allows for a longer "safe" circulatory arrest time that translates into more complete arch replacement in the presence of complex primary arch tears.

ABSTRACT 110

BIOGLUE(WITH ACUTE TYPE A AORTIC DISSECTION: RESULTS FROM 87 CONSECUTIVE REPAIRS

Alberto Pochettino, Thomas G. Gleason, Robert C. Gorman, G. William Moser, Joseph E. Bavaria

BACKGROUND: Surgery for acute type A aortic dissection requires repair of the aortic wall at the proximal extent below the sinotubular ridge or the aortic root must be replaced. Various tissue adhesives have been used to create a neomedia in dissected sinus segments. This series reports the largest experience using BioGlue (for neomedia reconstruction at the proximal- and distal-most extents of acute type A dissection).

METHODS: Between 3/2000 and 10/2002 87 consecutive patients underwent repair of acute type A dissection (67 root repairs, 20 root replacements). An integrated approach with rapid delivery to the OR, continuous EEG monitoring, and intraoperative TEE was used exclusively. Operative technique uniformly included: valve repair/resuspension, repair of the aortic media using BioGlue (with or without Teflon felt in the sinuses and the arch, ascending aortic replacement and hemiarch reconstruction using hypothermic circulatory arrest (HCA) with retrograde cerebral perfusion (RCP)).

RESULTS: Among the root repairs, the mean age was 64 (range 25-86). Cardiopulmonary bypass time, cross-clamp time, and HCA time averaged 199 (45), 143 (45), and 39 (11) min, respectively. Length of stay averaged 12.6 (2 days (range 3-70)). Three patients required reoperation for bleeding, and there were two post operative strokes. Thirty-day and in-hospital mortality rates were 4.9% and 6.6%, respectively. 12-month follow-up yielded no additional deaths and no reoperations.

CONCLUSION: Use of BioGlue is a safe and effective adjunct for repair of acute type A dissection. The mortality rate is low when an integrated approach is used. Intermediate durability (2.5 years) of the proximal and distal neomedia repair remains very satisfactory.

SATURDAY
MORNING

ABSTRACT 111

AORTIC LEAFLET REPLACEMENT WITH THE NEW 3F STENTLESS AORTIC BIOPROSTHESIS. CLINICAL EVALUATION OF HEMODYNAMIC PERFORMANCE AND CORONARY FLOW

Mirko Doss;

Frankfurt am Main, Hessen, Germany

BACKGROUND: The 3F aortic bioprosthesis is a stentless biological heart valve fabricated from three equal leaflets of equine pericardium, assembled in a tubular shape, and implanted in the native aortic root, to replace the patient's diseased aortic leaflets. Clinical trials began October 2001 and being one of the first centres to implant this prosthesis in humans, we would like to present our experiences with this new device.

METHODS: Between January 2002 and August 2002, 24 3F aortic bioprosthesis were implanted at our institution. Effective orifice area, mean gradients and ejection fraction were evaluated echocardiographically at discharge and 6 months after surgery. Furthermore coronary flow before and after the implantation of the device were assessed via MRI-angiography.

RESULTS: At 6 months of follow-up the 3F bioprosthesis showed a good hemodynamic performance with a significant drop of mean gradients to 15.9 mmHg, a mean effective orifice area of 1.7 cm² and a mean ejection fraction of 61.5%. Coronary flow had significantly improved compared to preoperative values and reversal of preoperative systolic flow was abolished.

CONCLUSION: The clinical performance of the new 3F aortic bioprosthesis is comparable to regular stentless aortic valves. Its unique design features make it easier and quicker to implant than conventional stentless valves additionally an excellent restoration of coronary flow is achieved by this prosthesis.

ABSTRACT 112

OPTIMUM ORIENTATION LEADS TO INCREASED CORONARY FLOW FOLLOWING MECHANICAL AORTIC VALVE REPLACEMENT.Peter Klein;

University Hospital Frankfurt am Main, Frankfurt, Germany

OBJECTIVE: Optimum orientation of mechanical aortic valves was defined in previous studies regarding systolic performance. The tilting disc valve matched flow dynamics in the proximal aorta almost physiologically, when its major orifice faced the noncoronary sinus, the area of highest velocities during ejection. Optimum orientation for the bileaflet design was achieved with one leaflet opening towards the right coronary sinus. The present study investigates the influence of valve orientation on coronary flow for both valve designs in an animal setup.

METHODS: A rotation device designed to hold either a Medtronic Hall tilting disc or St. Jude Medical bileaflet aortic valve was implanted into 8 pigs. The device allowed rotation of the implanted valve without reopening the aorta. Coronary blood flow in the left anterior descending artery (LAD) was measured at a constant cardiac output preoperatively and in different orientations of the valves (best and worst position as defined previously) using a perivascular ultrasound device.

RESULTS: The coronary flow rates are summarized in Table 1.

	Tilting disc (n=4)	Bileaflet (n=4)
Preoperatively	24.5 (± 4.7) ml	25 (± 3.3) ml
Best orientation	64 (± 8.7) ml	46 (± 9.7) ml
Worst orientation	37.5 (± 1.3) ml	34 (± 9) ml

CONCLUSIONS: Coronary blood flow was significantly influenced by mechanical aortic valve implantation ($p < 0.01$) and by the orientation of the implanted valves ($p < 0.05$). For both valve designs the previously defined optimum orientation demonstrated the highest LAD flow rates with significantly higher LAD flow in the tilting disc valves ($p < 0.02$).

SATURDAY
MORNING

ABSTRACT 113

CARDIAC AUTOTRANSPLANTATION: A SALVAGE TECHNIQUE FOR MITRAL VALVE REPLACEMENT

Dimitri Novitzky, MD.

Tampa Va Medical Center and the University of South Florida, Tampa, Florida, USA

BACKGROUND : Adequate exposure is a fundamental requirement in mitral valve (MV) surgery. Occasionally seeking adequate exposure may be technically demanding and often challenging to the surgeon. In 1995, a 69-year-old male required MV replacement and concomitant coronary artery bypass grafting (CABG). Distal coronary grafts were performed initially followed by exposure of the MV through a transatrial-septal approach. Adequate exposure was unable to be achieved and the heart was explanted. The MV was replaced ex vivo and autotransplantation of the heart was subsequently performed. Proximal coronary anastomoses were completed and a permanent pacemaker was implanted. The patient had an uneventful recovery and was discharged from the hospital.

METHODS: To assess the incident of inadequate MV exposure, a survey was forwarded to 3,000 cardiac surgeons. A total of 1,120 responses were received. This represents at 37.3% response rate.

RESULTS: Seven hundred eight four respondents (70.0%) indicated they had experienced difficulty in achieving adequate exposure of the MV at one time or another. To achieve adequate exposure, 392 (50.0%) indicated they would extend the initial atriotomy perpendicular to the incision in the atrial groove and into the right atrium and then subsequently divide the atrial septum. Using these techniques, 213 respondents (19.0%) reported similar problems. In those cases, 190 respondents (17.0%) proceeded to divide the superior vena cava (SVC) and 11 (1.0%) divided the inferior vena cava (IVC) and 11 (1.0%) separated both the SVC and the IVC. Forty-four respondents (3.9%) indicated they had been forced at one time or another to abort the MV procedure and discontinue cardiopulmonary bypass without performing the indicated MV surgery. This action was reported in 71 patients. In the experience of this group of 1,120 cardiac surgeons it was reported that 320 operative deaths could be directly attributed in one way or another to incomplete MV surgery as a result of inadequate exposure and access to the MV annulus.

CONCLUSIONS: While technically demanding, in experienced hands, cardiac autotransplantation may be a viable alternative for MV replacement when difficulty is encountered with adequate exposure. This approach may reduce the incidence of incomplete operation and provide enhanced clinical outcomes.

ABSTRACT 114

A NEW STENTLESS BOVINE PERICARDIAL PROSTHESIS FOR MITRAL VALVE REPLACEMENT: PRELIMINARY EXPERIENCE

Zohair Al Halees, MD.
Saudi Arabia

OBJECTIVE: The SJM Quattro Mitral Valve is manufactured from bovine pericardium that has been cross-linked using a glutaraldehyde solution. This is a quadrileaflet stentless bovine pericardial bioprosthesis (QMV), with anticalcification treatment is indicated for the replacement of malfunctioning native or prosthetic mitral valves.

METHODS: From March 1998 – September 2002, 40 SJM QMV were used to replace the MV in 39 patients (pts) (one patient had two valves). Mean age 35 ± 15 , range 16-76. Mean NYHA functional class 2.5 ± 1.5 . Severe mitral regurgitation (MR), in 20 patients, 7 severe mitral stenosis, 12 mixed lesions, 16 had previous surgery with previous prosthesis. Etiology: 22 patients rheumatic, 6 degenerative, 9 degenerated bioprosthesis 1 mechanical valve thrombosis and 2 endocarditis.

RESULTS: Hospital mortality 1/39 (2.5%), 2 late deaths. One patient developed minor stroke and recovered. Four patients developed endocarditis requiring reoperation. A fifth patient who had a Ross procedure and QMV replacement died of septic shock with prosthetic mitral valve endocarditis prior to reoperation. Freedom from endocarditis is $74\% \pm 10\%$. Mean follow up 20 ± 14 months, range 4-48. Mean MV area $2.1 \pm 0.06\text{cm}^2$ MR trivial to mild in all pts except 4 who have mild to moderate MR. One of those 4 had the QMV explanted and replaced somewhere else 3 years later. All surviving patients are asymptomatic.

CONCLUSION: It is feasible to implant this valve for various MV pathologies even after previous prosthesis. Hemodynamics are acceptable. Longer follow-up awaited.

SATURDAY
MORNING

ABSTRACT 181

THE NEW EDWARDS PERIMOUNT MAGNA VALVE

E. Wolner, N. Simon-Kupilik, P. Simon
Dept. Cardio-Thoracic Surgery, University Vienna

The PERIMOUNT Magna valve is a new generation pericardial valve designed for improved durability and hemodynamics. New tissue selection and valve construction methods have been introduced to enhance durability, and to prevent calcification the XenoLogiX treatment is applied. The valve has a supraannular design and a scalloped shape of the sewing ring to provide an optimal anatomic fit. A smaller sewing ring diameter should allow for a larger valve in a given patient's annulus compared with the standard PERIMOUNT valve.

Since September 2002, 200 valves were implanted in 26 centers in Canada and Europe. Our own experience consists of 20 valve implants in patients over the age of 70 years. We were able in 12 patients to use a bigger valve as measured with a standard PERIMOUNT sizer. The gradients and hemolysis were low. There were no postoperative complications.

CONCLUSION: The hemodynamic performance of the PERIMOUNT Magna valve is superior to other stented valves, and with its implant ease and reproducible results, the availability of this new valve obviates the need for stentless valves and aortic root enlargement procedures. Further observation will prove the effectiveness of the XenoLogiX anticalcification treatment and the other design enhancements aimed at improving durability.

Saturday, March 22, 2003

Scientific Session VII
Featured Abstracts

Abstracts 115 - 118

(Grand Ballroom)

SATURDAY
MORNING

ABSTRACT 115

**ENDOVASCULAR TREATMENT OF THE THORACIC AORTA:
PROSPECTIVE STUDY**

A.S. Bortone, D. D'Agostino, E. De Cillis, G. Mannatrizio, V. Paradiso,
G. Dialetto*, M. Cotrufo*, L. de Luca Tupputi Schinosa.
Cardiac Surgery University of Bari and *Naples - ITALY

METHODS: From March 1999 to November 2002, 71 pts underwent to our observation: 20 with atherosclerotic aneurysms, 17 post-traumatic and 22 type B dissections. 12 pts with chronic type B dissection were not suitable of endovascular and therefore medical treatment was implemented.

RESULTS: There were two hospital deaths (3.4%) respectively due to multiorgan failure and rupture of ascending aorta owing to device dislodgement. An optimal sealing of the graft was reached in 98, 3%. However, one pt required open surgical conversion while seven underwent left carotid-subclavian bypass. In two pts iliac fenestration was performed. No spinal cord injuries were observed. At the follow-up by angio-CT scan within 72 hrs and after 6, 12 months and once a year, no stent-graft related complications have been detected. In two pts with chronic dissection an asymptomatic type II endoleak was found. On the other hand 41.6% of medical treatment pts died.

CONCLUSION: Endoluminal stent-graft treatment represents a valid option by itself especially if compared to medical therapy.

ABSTRACT 116

PROSPECTIVE ANALYSIS OF OFF-PUMP CABG IN ACUTE MYOCARDIAL INFARCTION

M. J. Jasinski MD, FETCS, S. Wos MD, PhD, R. Bachowski MD, W. Ceglarek MD, K. Widenka MD, M. Gemel MD, W. Domaradzki MD, M. Deja MD, A. Szafranek MD, P. Olszówka MD, D. Szurlej MD
2nd Dept. of Cardiac Surgery Medical University of Silesia, Katowice, Poland

PURPOSE: Conventional CABG using cardiopulmonary bypass (CPB) carries higher mortality and morbidity for patients operated upon acute myocardial infarction (AMI) and acute coronary syndrome (ACS). Aim of this prospective study was to evaluate risk factors for off- pump CABG (OPCAB) in ACS and AMI.

METHODS: Since December 1999 till August 2002, 165 consecutive urgent and emergency CABG patients due to AMI referred to one surgeon were operated without CPB. All of those 165 ACS were troponine positive (by definition), among them there were 46 AMI operated during first 72 hours- group named "AMI early" Sixteen preoperative and operative discrete variables (age, sex, ejection fraction, myocardial infarction, acute myocardial infarct (<1 week), myocardial infarct (> 1 week), acute coronary syndrome, CCS class, NYHA class, hypertension, diabetes mellitus, renal failure, chronic obstructive pulmonary disease, redo, atheroscleromathosis, LV aneurysm) were tested, with end-points being 30-day hospital mortality.

RESULTS: Overall 30-day mortality was 4.24% (n=7) for ACS group and 10, 9% (n=5) for "AMI early" group. Univariate analysis revealed operation in AMI < 72 hours ("AMI early") as only predictor (p=0,022, OR- 7, 07, CI- 1, 3- 37,5). Multivariate logistic regression analysis for overall 165 patients revealed "AMI early" (p=0, 03, OR-8,6), female gender (p=0,01, OR-15,7), LV aneurysm (p=0,03,OR-13,8), perioperative IABP (p=0,03, OR-12) and renal failure (p=0,05, OR-2) as independent risk factors for 30-day mortality. In "AMI early" group female gender (p= 0.001, OR- 32, 5), perioperative IABP (p=0, 03, OR- 12,1) and diabetes (p=0,05, OR-2,1) appeared to be the risk factors.

CONCLUSIONS: OPCAB is a valuable approach in AMI; however it carries significant mortality and morbidity when performed within 72 hours of myocardial infarction. Careful preselection, early preoperative IABP support and timing of intervention warrant optimal results.

ABSTRACT 117

EPICARDIAL LEADS ARE SUPERIOR TO CORONARY SINUS LEADS IN BIVENTRICULAR PACING

H. Mair; A. Schütz; K. Warncke; M. Schmöckel; G. Nollert; S. Däbritz;
B. ReichartGroßhadern Medical Center, Cardiac Surgery, Munich, Germany

OBJECTIVE: Biventricular pacing has shown improvements in cardiac function and congestive heart failure (CHF). We aimed to evaluate different operative techniques.

METHODS: Since April 1999 58 patients (pts, age: 67 ± 11 years) with depressed ejection fraction ($23 \pm 9\%$), left bundle-branch-bloc (QRS 171 ± 32 ms) and NYHA III or higher were enrolled. For biventricular stimulation we used coronary sinus (cs) leads in 46 pts (Medtronic2187 and Guidant-Easytrek). In 12 pts epicardial steroid leads (Medtronic 4968) were placed through a small left-lateral thoracotomy (7 ± 3 cm). 21 pts needed a defibrillator. Follow up time was 9-44 month (median: 24,3 month).

RESULTS: In biventricular mode patients had significant improvement of NYHA-class ($p < 0.0001$), QRS decreased to 144 ± 22 ms ($p < 0.001$) and the 6-min-walk-test improved from 320 ± 110 m preoperatively to 480 ± 82 m after 12 month and 496 ± 105 m after 36 month ($p < 0.001$) in both groups.

After 12 month the stimulation-threshold of the cs-leads were significantly higher compared to epicardial leads ($2,2 \pm 0,8$ V/ $0,5$ ms vs. $1,0 \pm 0,3$ V/ $0,5$ ms) and increased in the follow-up ($2,6 \pm 0,7$ V/ $0,5$ ms) vs. threshold of epicardial leads did not increase ($p < 0.001$). At 12 month follow up, 8 cs-leads had a threshold of >4 V/ $0,5$ ms vs. epicardial leads were all under 2V/ $0,5$ ms. After cs-lead implantation 7 devices failed and needed conversion to epicardial leads (loss of pacing capture, diaphragm stimulation or lead dislodgment), vs. epimyocardial leads needed no reoperation. There were no severe intraoperative complications in any group. 2 pts died due to ventricular fibrillation and one for non cardiac reason.

CONCLUSION: Epicardial leads revealed excellent long-term results. Therefore epicardial implantation is a safe and reliable technique and should be offered to patients.

ABSTRACT 118

CONCOMITANT MICROWAVE ABLATION - A SUPERIOR CONCEPT FOR CURATIVE TREATMENT OF PERMANENT ATRIAL FIBRILLATION IN COMPARISON TO CARDIOSURGICAL PROCEDURES ALONE

M. Knaut, S. M. Tugtekin, V. Gulielmos
Heart Center Dresden University Hospital, Dept. of Cardiac Surgery;
Dresden, Germany

INTRODUCTION: Microwave ablation (MW) is a safe and efficient procedure for the treatment of permanent atrial fibrillation (pAF). Restoring of sinus rhythm (SR) is of major importance due to the co-morbidity and co-mortality associated with pAF.

METHODS: Two patient groups with mitral valve disease (MVD), coronary artery disease (CAD) and aortic valve disease (AVD) were compared retrospectively. Group A includes 62 patients (pts) (age 72 ± 9 years, ejection fraction 25 - 74%, left atrial diameter 53 ± 9 mm, MVD in 34 pts, CAD in 53 pts, AVD in 40 pts, pAF for 6.9 ± 5.5 years) and group B 88 pts (age 67 ± 4 years, ejection fraction 26-76%, left atrial diameter 52 ± 6 mm, MVD in 82 pts, CAD in 60 pts, AVD in 18 pts, pAF for 6.4 ± 4 years). In group B concomitant MW was performed.

RESULTS: Survival rate was 94.2% (group A) vs. 98% (group B). In the 1-year follow-up in group A 7% of pts with MVD, 9% with CAD, and 5% of pts with AVD were in SR. In group B 62% of pts with MVD, 72% with CAD, and 83% of pts with AVD were in SR.

CONCLUSIONS: MW is efficient and safe in pts with pAF and concomitant cardiosurgical procedures, independently from the nature of cardiac disease in comparison to isolated cardiosurgical procedures. We have extended this approach to most pts with pAF and cardiosurgical disease.

SATURDAY
MORNING

Poster Presentations

Abstracts 22, 119 - 174

POSTER
PRESENTATIONS

ABSTRACT 119

DISTRACTION ANGIOGENESIS

Jack C. Griffis

AIM: Distraction angiogenesis was evaluated as a potential means for generating an autologous arterial vascular graft. A distraction device was designed and implanted in swine. The gastroepiploic artery was distended successfully at rates averaging approximately 10mm/day with minimal effects on the normal histology of the artery.

METHODS: A mechanical means of producing axial arterial distraction was developed and evaluated in-vivo. Juvenile swine were utilized for the study. Seven pigs were entered in the study. The gastroepiploic artery of each animal was utilized to assess the effects of mechanical stimuli, and the gastroepiploic artery segments proximal and distal to the implant were designated as the control. Upon completion of device actuation, the mechanism was removed and designated artery segments evaluated using gross visual histological examination.

RESULTS: Axial arterial length change occurred without significant adverse histomorphometric changes. Significant changes in arterial length did not result in elastic recoil upon removal from the mechanism and examination. Patency was maintained in vessels that incurred up to 7.8mm/day distraction, or 42% per day increased length. Results are summarized based upon two distinct distraction subgroups (Standard and Hyper). Mean graft length changes for the total artery segment were 8.25mm (33%) and 11.27mm (45%) per day, respectively.

ABSTRACT 120

HEART VALVE REPAIRJeffrey H. Shuhaiber

University of Illinois, Department of Surgery, Chicago, Illinois, USA

Heart valve repair is biomaterial dependent. Autogenous tissue for valvular reconstruction is limited to pericardium and fascia lata. More clinical studies recommend valve repair to replacement. I forward a potential hypothesis for valve repair using the plantaris tendon extrapolated from hand surgery. This provides a new foundation to increase the autogenous donor tissue for valve repair and enhance the surgeon's armamentarium. The poster will address a novel and unique approach in harvesting, on table reconstruction of the atrioventricular annulus, chordae and papillary muscle complex. The poster will exhibit these techniques diagrammatically. The intention is to improve the art and science of surgery for future clinical development.

ABSTRACT 121

QUALITY OF LIFE AFTER MIDCAB AND OPCAB PROCEDURES

Arndt-H. Kiessling, Frank Isgro, Pierre Thierry Noah, Werner Saggau
Heart Institute Ludwigshafen, Ludwigshafen, Germany

BACKGROUND: The beneficial aspects of minimal invasive procedures are still in discussion. To evaluate the quality of life, we performed a follow up questionnaire after MIDCAB and OPCAB operations.

METHODS: From 01/06/2000 to 31/05/2002, in 125 patients (mean age 61.9 ± 10.4 years; 75.1% male) a follow up, using a standardized catalogue of questions concerning quality of life and operation related complication. Majority of patients referred to OPCAB (59.5%), MIDCAB without ECC (25.5%) and with ECC (15%). The Barthel mobility index and geriatric depression scale were used in order to evaluate physical ability and mood disturbances.

RESULTS: The inhospital mortality reached 0.6 %. 6.1% patients died between hospital discharge and follow-up. Rehospitalisation due to various clinical diagnoses was necessary in 12.8%. Without any group differences, patients had a normal geriatric depression scale in 98.1% and a regular Barthel index in 97.2. Wound healing disturbances were higher in the MIDCAB group.

CONCLUSION: Compare to follow up examinations in patients with full sternotomy and ECC, your results show a better outcome in the postoperative course. However, the patient selection for an OPCAB or MIDCAB procedure is still different in our institution.

ABSTRACT 122

BEATING-HEART VALVE SURGERY IN PATIENTS WITH RENAL FAILURE REQUIRING HEMODIALYSIS

Saqib Masroor, MD, Pierluca Lombardi, MD, Hassan Tehrani, MD, Kushagra Katariya, MD and Tomas Salerno, MD

BACKGROUND: We evaluated the safety and efficacy of beating-heart valve surgery as a myocardial protection strategy in patients with renal failure requiring hemodialysis.

METHODS: This is a retrospective review of 8 patients with renal failure requiring hemodialysis, who underwent beating-heart valve surgery at our institution between April 2000 and December 2001.

RESULTS: There were 4 males in the group. Mean age was 45.8 (13.8) years, with a mean duration of hemodialysis of 49 (48) months. The procedures included MVR (4), AVR (1), AVR/MVR (1), AVR/CABG (1) and mitral and tricuspid valve repair (1). The etiology was infectious endocarditis in 4 and degenerative disease in the rest. Mean cardiopulmonary bypass time was 78.6 (8.17) minutes. One patient was extubated in the operating room while the rest were extubated 4-24 hours postoperatively. Two patients died in the entire group. One of these patients was septic for two weeks requiring inotropes preoperatively, who died on the 79th postoperative day from uncontrolled yeast and bacterial sepsis and multi-organ failure. The other patient died from a large hemorrhagic stroke during anticoagulation on the 5th postoperative day. Average length of hospital ICU stay was 15.3 (32.5) days and hospital stay was 18.8 (28.8) days. Excluding the septic patient who was moribund preoperatively as mentioned above, the average length of ICU stay was 2.8 (2) days and hospital stay was 8.4 (2.9) days. Other complications included re-intubation for < 24 hours (1), AV graft thrombosis (1) and stroke (1, same patient mentioned above). There were no new cardiac (including arrhythmia and low cardiac output syndrome) or metabolic complications (including hyperkalemia, fluid overload).

CONCLUSIONS: Beating-heart valve surgery can be performed safely in patients with renal failure requiring hemodialysis. Although this is a small study, the results suggest a low incidence of complications and short ICU and hospital stay.

ABSTRACT 123

NORMOTHERMIA AFFECTS IMMUNE RESPONSE REGULATION AND ATTENUATES MYOCARDIAL DAMAGE DURING OFF-PUMP CORONARY ARTERY BYPASS (OPCAB) SURGERY

Nahum Neshet,* Steven Insler,** Ina Froilkis,* Gil Bolotin,* Josef Paz,* Amir Kramer,* Dimitry Pevni,* Menahem Matza,* Oren Lev-Ran,* Ram Sharony,* Gideon Uretzky*

*The Department of Cardiothoracic Surgery, Tel-Aviv Sourasky Medical Center, Tel-Aviv University, Tel-Aviv, Israel. **Cleveland Clinic Foundation, Cleveland, Ohio, US.

BACKGROUND: Perioperative hypothermia is associated with impaired immune function. We assessed the effects of maintaining normothermia on immune function and on myocardial performance during OPCAB surgery in two medical centers.

METHODS: Eighty patients undergoing OPCAB surgery were randomized into two groups and warmed perioperatively with Allon thermoregulation (AT, n=40) or with other routine thermal care (RTC, n=40). AT used patients' urinary bladder (core) temperature values to maintain water temperature in a circulating garment at 37°C. Patient temperature, hemodynamics, cardiac Troponin I (cTnI) and interleukin (IL)-6, -8 and -10 levels were uninterruptedly assessed perioperatively.

RESULTS: Cardiac index (CI; L/min) tested at 5 time points was higher in AT patients compared to RTC patients (P<0.05). Systemic vascular resistance (SVR, [dyne*sec]/cm⁵) was lower in AT patients during the entire perioperative period (P<0.05). IL levels were higher than baseline levels in both groups at the end of surgery: from 1- 10 pg/ml at baseline and up to 25: 88 pg/ml at the end of surgery (P<0.001). IL levels were higher in the RTC group (P<0.005). Cardiac troponin I (cTnI) levels were elevated during the entire perioperative period, suggesting some degree of myocardial damage, but was lower in AT group. cTnI levels correlated with IL-6, IL-8 and IL-10 values.

CONCLUSIONS: OPCAB surgery was associated with clear alternation of the immune regulation as expressed by different elevations of the investigated cytokines. The clear and significant correlation between IL-6 and cTnI suggests a direct damaging effect of IL-6 on the myocardium. Maintenance of normothermia throughout the entire perioperative period showed reduced levels of IL-6 and IL-10, suggesting enhanced immune response to stress.

ABSTRACT 125

BIOMECHANICAL COMPARISON OF TWO STERNAL CLOSURE METHODS

David H. Song, MD

University of Chicago Hospitals, Chicago, IL, USA

BACKGROUND: Previous stress tests performed on a cadaver sternal model have shown significant separation (2mm or greater) with circlage closure under normal physiologic forces. A validated foam model (density 20 lbs./ft³) is used to compare circlage wire closure to titanium plate closure.

METHODS: Ten sternal models were closed with 2 different techniques: half with 6 circlage wires and half with 6 titanium 2.4mm plates and screws. Models were mounted on a traction device delivering lateral pull forces at increments of 20 N up to 400 N (90 lbs). Separation was measured in mm.

RESULTS: Significant differences between the two closure techniques were noted upon comparison at the mid-sternum at 40 N and greater and the xyphoid at 80 N and greater ($p < 0.05$ T-test). Significant separation of 2mm or greater was seen in all models closed with wire, no significant separation was seen in any models closed with plates.

CONCLUSIONS: Normal physiologic forces can disrupt sternal closure performed with wire. This disruption is believed by many to be an antecedent event to sternal breakdown and post-operative mediastinitis. Sternal closure using titanium plates and screws is shown to be significantly superior to wire closure in this validated polyurethane foam model

ABSTRACT 126

THREE YEARS OF OPCAB PROGRAM: WHAT WE LEARN AFTER MORE THEN EIGHT HUNDRED CASES

Milani R., Bofman P., Varela A., Giffhorn H., Guimarães M. , Souza J. A., Pantarolli R., Maia F., Zytysnski L.A., Silveira A.
Cardiovascular Surgery Department – Aliança Saúde – PUC/Pr - Curitiba - Paraná - Brazil

OBJECTIVES: This retrospective study was designed to analyze our experience with more then eight hundred cases of OPCAB myocardial revascularization, the difficult and pitfalls.

METHODS: From June 1999 to October 2002, 882 patients were submitted to OPCAB myocardial revascularization, corresponding to more than 80% (81.9%) of our total coronary surgery. Since we started an OPCAB program on 1999 we had an increase in our coronary surgery without extracorporeal circulation. On 1999 we did 103 cases, corresponding to 50.2% of our coronary surgery. On 2000, we did 139 cases corresponding to 67.1%. On 2001, 291 cases were done, corresponding to 92.9%, and on 2002, we have done 99.1% of our coronary surgery off-pump. The great majority of the patients were male, 595 patients (67.5%), with a mean age of 67.7 years. The patients were operated off-pump, with 2mg/kg of heparin and the operations techniques consisted of proximal coronary artery snared, LIMA'S suture and coronary stabilization. Sometimes we used intracoronary shunt, especially for right coronary artery. The distal anastomosis was done first as routine. After finished all the anastomosis the heparin was reverted in 75% of the initial dose.

RESULTS: The total number of distal anastomosis were 2629, with 2.98 grafts per patient. Eighty four percent of the patients received LIMA and forty four percent received only arterial grafts. The average time for intensive care unit stay was 25.3 hours and for hospital stay was 5.2 days. Regarding complications, 2.64% of the patients presented acute myocardial infarction. Mediastinitis, acute renal insufficiency, stroke, reintervention for bleeding and on-pump crossover showed rates lower then 1%. The global mortality were 3.62%, with 689 elective patients presented 2.03% of mortality, 93 reoperations patients presented 6.45% of mortality and 56 emergency patients, with cardiogenic shock, presented a mortality rate of 21.4%. The majority of the deaths were caused by acute myocardial infarction, followed by metabolic disorders, stroke, bleeding and mediastinitis respectively.

CONCLUSION: At the present moment, we are doing OPCAB in more than 99% of the patients submitted to myocardial revascularization. After this series, we conclude that all patients needing myocardial revascularization can receive OPCAB surgery, even patients in whom you have to do five or six anastomosis, patients with a poor left ventricle function and patients with important other disease then cardiac. OPCAB can reach benefits for low and high risk patients. In conclusion, OPCAB is a safety procedure, with low risk of complications and great benefits, specially for high risk patients. The three major objectives of this technique are: good heart stabilization leading to a good exposure of the target vessel and finally a perfect anastomosis. This is possible.

ABSTRACT 127

PROBLEMS IN AN OBJECTIVE EVALUATION OF THE GRAFT PATENCY AFTER MIDCAB AND OPCAB SURGERY.

Ernst Weigang 1, Johannes Roysl 1, Andreas Dencker 1, Joachim Schoellhorn 1, Andreas van de Loo 2, Friedhelm Beyersdorf 1

1 Department of Cardiovascular Surgery, University Hospital Freiburg, Germany

2 Department of Cardiology, University Hospital Freiburg, Germany

OBJECTIVE: We wanted to evaluate the graft patency in all patients that have undergone MIDCAB (29 patients) and OPCAB (60 patients) surgery in our department.

METHODS: All surviving patients (n=87) were invited for a follow-up examination. An angiographic control was recommended.

RESULTS: 19 patients had already received an angiographic control due to clinical problems. Out of the remaining 68 patients 27 angiographic controls could be performed. 18 patients did not show up for follow-up examination, 20 patients did not agree to the angiography. In three cases the primary physician opposed the suggested control. In total angiographic controls were performed in 46/89 patients (52%) and 53 anastomoses revealing a graft patency rate of 89% (Tab.). In those 27 patients without symptoms we found a patency rate of 97%. In the group of 19 patients with symptoms the graft patency was 78%. This group showed a significantly higher proportion of stenoses or occlusion.

	total	without symptoms	with symptoms	
No. of patients	46	27	19	
months after CABG (mean)	17.7	21.7	12.2	
patients without occlusion	40 (87%)	26 (96%)	14 (74%)	not significant
patients without stenosis	35 (76%)	24 (89%)	11 (58%)	p < 0.05
No. of anastomoses	53	30	23	
anastomoses not occluded	47 (89%)	29 (97%)	18 (78%)	not significant
anastomoses without stenosis	42 (79%)	27 (90%)	15 (65%)	p < 0.05
stenosis 51-75%	3 (6%)	2 (7%)	1 (4%)	
stenosis >75%	2 (4%)	0 (0%)	2 (9%)	

Tab. Angiographic results from 46 patients divided into patients with and without symptoms.

CONCLUSIONS: Not all patients and primary physicians could be convinced of the necessity of the angiographic control when no clinical complaints were present. Those patients with symptoms had angiographies in 100%. Therefore we have a negative bias in our results. The difficulty to gain unbiased and complete data remains.

ABSTRACT 128

THE USE OF HETEROTOPIC HEART TRANSPLANTATION IN EXPERIMENTAL SURGERY

Jorge Roda

Hospital Puerta de Hierro, Madrid, Spain

INTRODUCTION: The use of heterotopic heart transplantation (HHT) in experimental surgery is an extended method to evaluate cardiac graft viability. To study endothelial injury after ischemia-reperfusion, the technique described by Matsui et al for HHT was chosen. With the purpose of using this technique in small pigs, a modification, which consists of replacing the atrium-to-atrium anastomosis for the tip of a venous cannula 30F, was developed. Both techniques were compared.

METHODS: Twenty seven consecutive HHT in 15-20 kg pigs using Matsui's original technique and the modified technique were performed. Ischemia time, bleeding volume, mean gradient and anastomosis complications were measured to compare both techniques.

RESULTS: Statistical significant decreases in ischemia time, bleeding volume and mean gradient with the modified technique were found. Furthermore, there were two cases of suture dehiscence with the original technique.

CONCLUSIONS: The replacement of the atrium-to-atrium anastomosis for the venous cannula is a modification that statically decreases the ischemia time, blood loss and avoids suture complications. This modification makes Matsui's technique easier, faster and safer in small pigs and it may be used in bigger animals and in any kind of non-permanent anastomosis.

ABSTRACT 130

PERI-OPERATIVE ASSESSMENT OF LEFT VENTRICULAR FUNCTION BY PRESSURE-VOLUME LOOPS USING THE CONDUCTANCE CATHETER METHOD

Sven Tulner, Robert Klautz, Frank Engbers, Jan Baan, Ernst vander Wall, Robert Dion, Paul Steendijk
Cardiothoracic Surgery and Cardiology, Leiden University Medical Center, The Netherlands

Peri-operative quantification of LV function by pressure-volume relations is advantageous, since load-independent indices are obtained. In 8 CABG patients we obtained pressure-volume loops using the conductance catheter. Measurements, at paced heart rate of 80 beats/minute, were obtained before and after CPB at steady state and during preload reduction by temporary occlusion of the inferior caval vein. Complete data were acquired within 15 minutes before cannulation and after decannulation. CO (5.2 ± 1.3 to 6.0 ± 1.4 L/min, p=NS) and EF (46 ± 17 to $48 \pm 19\%$, p=NS) did not change, however end-diastolic pressure increased significantly (8 ± 2 to 16 ± 7 , p<0.05). Load-independent systolic indices remained constant (elastance: 1.31 ± 1.20 to 1.13 ± 0.59 mmHg/mL, p=NS). Diastolic function changed significantly as tau decreased from 64 ± 6 to 52 ± 5 ms (p<0.05) and chamber stiffness increased from 0.016 ± 0.014 to 0.038 ± 0.016 1/ml (p<0.05). All patients remained hemodynamically stable and no complications occurred.

CONCLUSION: The conductance catheter provides accurate data on peri-operative LV function and is an important tool to evaluate the effects of new surgical and anesthetic procedures.

ABSTRACT 132

EXPERIENCE WITH AN ALBUMIN-GLUTARALDEHYDE TISSUE ADHESIVE IN SEALING AIR LEAKS AFTER BULLECTOMY

Konstantinos Potaris, MD, Peter Mihos, MD, Ioannis Gakidis, MD.
Department of Thoracic Surgery, General Hospital of Attica 'KAT', Kifissia, Greece.

OBJECTIVE: To evaluate the efficacy of an albumin-glutaraldehyde tissue adhesive (BioGlue®, CryoLife Inc., Kennesaw, GA) in preventing air leaks after bullectomy. Between January 1999 and June 2002 BioGlue® was applied in 21 consecutive patients, who underwent resection of bullae for persistent or recurrent pneumothorax. A control group of 19 patients matched for age and sex was used to compare results.

RESULTS: In the treatment group duration of air leak ranged from 0 to 2 days, with a mean of 0.42 days. Chest-tube drainage ranged from 2 to 4 days, with a mean of 2.33 days. In the control group duration of air leak ranged from 2 to 11 days, with a mean of 3.68 days. The chest tube drainage ranged from 3 to 12 days, with a mean of 5.42 days. There was no mortality and morbidity was less in the treatment group.

CONCLUSIONS: The use of BioGlue® as a surgical lung sealant decreased significantly postoperative air leak ($p < 0.001$) and time to chest tube removal ($p < 0.05$).

ABSTRACT 133

54-YEARS-OLD PATIENT PASSED AN OPEN MITRAL VALVE REPLACEMENT

Armand Molek, MD

Afula Medical Center, Afula, Israel

54-years-old patient passed an open mitral valve replacement. Left pleural effusion appeared a month after the surgery, it was drained, whereas lymphothorax was diagnosed. MCT diet was used, and the lymphatic drainage has alleviated. A month later breathlessness occurred, the patient was admitted for evaluation, and a large amount of pericardial effusion was found. In general anesthesia, VATS pericardial window was performed. Thick milky fluid was gained, and lymphopericardium was verified by biochemical examination of the fluid. Again, MCT diet was initialized, and the lymphatic discharge has ceased. The video tape shows the VATS performance of the pericardial window. As through the scope a small incision made on the pericardium, the milky discharge fountain-like breaks out from the pressurized pericardial cavity.

ABSTRACT 134

47-YEARS-OLD PATIENT PREVIOUSLY PASSED A MITRAL VALVE REPLACEMENT SURGERY

Armand Molek, MD

Afula Medical Center, Afula, Israel

47-years-old patient previously passed a mitral valve replacement surgery, he remained with a moderately reduced left ventricular function. He was seeking medical attention 2 months after the surgical operation due to breathlessness, in the chest X-ray and CT scans a moderate amount right pleural fluid was found. He was admitted to the chest surgery department for chest drainage, and a 32 Fr.tube was inserted into his right chest cavity, 2800 cc bloody stained exsudate was drained, but the patient immediately started to expectorate very large amount of serosous airway discharge consistent with pulmonary edema. In the X-ray no more pleural fluid was sees, but the entire right lung was opacified, whereas, the left was clean. Post-expansion pulmonary edema was diagnosed. Urgent intubation and mechanical ventillation was required. Forced diuresis was employed in the ICU, and during the next two days the right lung cleared up fully, and the patient was extubated. The case is an exellant example of post-expansion pulmonary edema, which can be expected, if rapid fluid evacuation is done from chest cavity. Fluid evacuation through a chest drain should be gradual.

ABSTRACT 135

LEFT VENTRICULAR PSEUDOANEURYSM SECONDARY TO LEFT VENTRICULAR APICAL VENTING.

Chiung-Lun Kao, MD, Jen-Ping Chang, MD

Division of Thoracic and Cardiovascular Surgery, Chang Gung Memorial Hospital at Kaohsiung, Taiwan, R.O.C.

A 79-year-old man suffered cardiac tamponade secondary to ruptured chronic type A aortic dissecting aneurysm 3 week ago, and he received patch repair of the chronic dissecting aneurysm under deep hypothermic circulatory arrest and left ventricular apical venting through a site more anterior to the true anatomic left ventricular apex. The venting site was repaired by means of 3-O polypropylene sutures with Teflon felt pledgets after pump-off. Ecchymosis of the epicardium around the apex was found, but hemostasis was achieved easily following manual compression. The postoperative course was uneventful, and he was discharged 7 days later. He received the computed tomographic (CT) scan of the chest to evaluate the post-repair ascending aorta during the outpatient visit, and the CT scan revealed a 3 × 4cm pseudoaneurysm over the apex of left ventricle.

The reoperation was performed through a repeat sternotomy by means of femoro-femoral bypass. A 3 × 4 cm pseudoaneurysm was found around the apex, and the pseudoaneurysm was entered under ventricular fibrillation due to the huge thrombotic ascending aortic aneurysm precluding cross-clamp. The perforation of the left ventricle communicating with the pseudoaneurysm was about 7mm in diameter, which was coinciding to the 18 Fr. left ventricular venting catheter. The perforation was repaired with 3-O pledgeted polypropylene suture, and the pseudoaneurysm was closed with linear repair. The patient was recovery well, and discharged 7 days postoperatively.

ABSTRACT 136

CORONARY PSEUDOANEURYSM AFTER FREESTYLE AORTIC ROOT REPLACEMENT

Chiung-Lun Kao

Chang Gung Memorial Hospital at Kaohsiung, Kaohsiung Hsien, Taiwan

A 65-year-old man had underwent total root replacement using a Freestyle stentless aortic root bioprosthesis (Medtronic, Minneapolis, MN, USA) with a Dacron tube graft extension for the type A aortic dissection associating aortic root aneurysm and severe aortic insufficiency 6 weeks ago. The postoperative course was uneventful, and he was scheduled for resection of the cholangiocarcinoma. On examination, the patient was mildly febrile (37.8oC) and hemodynamically stable. Hemogram showed decreased hemoglobin 9.6g/dL, and other blood chemistry results were within normal limits. The roentgenogram of the chest showed widening of the mediastinum. The computed tomographic scan revealed abnormal contrast material between the neo-aorta and the left coronary artery, and some blood clots around the neo-aorta.

Upon reoperation, a 2 × 1 cm pseudoaneurysm was found between the Freestyle bioprosthesis and the left coronary button, and the disruption of the suture line was, about 4mm in length, located at the upper part of the coronary anastomosis. The aortic wall was grossly free of infection, and the perforation was repaired with continuous 7-0 polypropylene suture. The postoperative course was complicated with Escherichia coli sepsis secondary to obstructive cholangitis, and the patient died 2weeks later.

ABSTRACT 137

TOWARDS TOTALLY GLUE CORONARY BYPASS

Evgenii V. Kolesov

Dnepropetrovsk State University, Ukraine

OBJECTIVE: The glue technique for CABG could be of interest especially for endoscopic and robotic surgery.

MATERIAL AND METHODS: We studied 78 different versions of end-to-side free arterial grafting to in situ coronary arteries made in vitro (cattle hearts) with cyanacrilic glue. The connections simulated IMA or A.radialis CABG.

Mean diameters of the vessels used :

grafts 1,84 mm (the least 1.2 mm)

coronaries 2.03 mm (the least 1.3 mm)

The major demands for the techniques were :

intima-to-intima adaptation

prevention of the glue penetration

The technique searching is continuing and the progress could be illustrated: in the whole group successful anastomosis was created in 88.4%, failed in 11.6%; in the last 21 experiments corresponding figures are 95.2% and 4.8%.

CONCLUSIONS: Despite the technique is still to be improved and tested in vivo it is clear that construction of totally glue vascular (IMA, A.radialis) anastomosis with the coronary arteries of less than 2 mm in diameter is feasible. Comparative study for the best suitable modern glue is to be done.

ABSTRACT 138

A NOVEL WAY TO PROTECT HEARTS FROM RE-PERFUSION INJURY

Kazuhiro Yamazaki

Cardiovascular Surgery, Graduat School of Medicine, Kyoto, Japan

PURPOSE: The aim of this study was to assess the efficacy of green tea polyphenol against cardioplegic re-perfusion injury. Methods: Sixteen rats were divided into two groups. Group A had 0.001M/l green tea polyphenol in oral uptake for 2 weeks (35ml/day in average). Group B had no medication. Isolated hearts were perfused with a Langendorff's apparatus. After equilibration, the hearts were arrested by St. Thomas solution. After 90 minutes' arrest with intermittent infusion of the cardioplegia every 30 minutes, the hearts were reperfused. Left ventricular (LV) function was measured just before arrest and after reperfusion. Then the hearts were evaluated with the immunohistochemical studies by 8-hydroxy-2'-deoxyguanosine (8-OhdG) as oxidative stress marker. For Group A, distribution of polyphenol was examined with FITC.

RESULTS: After reperfusion, in Group A the LV size became smaller. The heart weight ratio was lighter. The LV end systolic pressure volume relationship was higher. And also, the 8-OhdG index was lower in Group A. Labeled polyphenol was located in the cell membrane of cardiomyocyte. Conclusions: Green tea polyphenol given orally before the surgery protected hearts effectively. This simple and safe method may be applied to various treatments which require transient ischemia of the heart (e.g., off-pump CABG).

ABSTRACT 139

**HEART TRANSPLANTATION IN A PATIENT WITH ISOLATED
COMPACTION OF THE VENTRICULAR MYOCARDIUM**

Sotiris C. Stamou, M.D., 1, Edward E Lefrak, M.D.2

1. Section of Cardiac Surgery, Georgetown University Hospital,
Washington, D.C.
2. Inova Fairfax Hospital, Fairfax, Virginia

We describe an 18 year old patient with isolated non-compaction syndrome of the left ventricle, who presented to our institution with worsening congestive heart failure and was successfully treated with heart transplantation. The patient received an orthotopic heart transplant 5 months after symptom onset. Postoperative recovery after heart transplantation was uneventful. Only 6 cases of patients with non-compaction of the ventricular myocardium treated with heart transplantation have been described so far. Isolated non-compaction of the left ventricle is a rare entity that affect both sexes, age of presentation may vary and the clinical course is complicated by a worsening heart failure, serious arrhythmias and cardioembolic phenomena. Prompt recognition and diagnosis with echocardiogram and optimization of medical treatment is warranted. Unrelented cases are treated with cardiac transplantation. Prognosis of these patients is poor and main causes of death include arrhythmias, cardioembolic events and cardiac failure.

ABSTRACT 140

HEMORRHAGE-RELATED REEXPLORATION AFTER CONVENTIONAL VERSUS MINIMALLY INVASIVE CORONARY ARTERY BYPASS

Timothy L. Frankel, MS, Sotiris C. Stamou, MD, Ph.D, Robert C. Lowery, MD, Peter C. Hill, MD, Arvind K. Jain, MS, and Paul J. Corso, MD.
Sections of Cardiac Surgery Washington Hospital Center and Georgetown University Hospital, Washington, D.C., MedStar Research Institute, Washington, D.C.

BACKGROUND: Early results of coronary artery bypass without cardiopulmonary bypass (off-pump CABG) have demonstrated comparable outcomes over the conventional On-pump approach. It is unknown however, whether off-pump CABG may yield similar improvements in the hemorrhage-related reexploration rates.

METHODS: Between January 1998 and June 2002, 5,208 patients had Off-pump CABG and compared with a contemporaneous control group of 3,653 who underwent On-pump CABG, at the Washington Hospital Center. The patients undergoing Off-pump CABG were matched to on-pump patients by propensity score. A logistic regression model was used to test the difference in the postoperative hemorrhage-related reexploration rates and need for postoperative blood transfusions between groups, controlling for preoperative risk factors.

RESULTS: Patients undergoing Off-pump CABG had a lower trend of hemorrhage-related reexploration (Odds-Ratio [OR] = 0.69, 95% Confidence Intervals [CI] = 0.46-1.04, p=0.08) and decreased need for postoperative blood transfusions (OR = 0.56, CI = 0.5-0.63, p<0.01) compared to On-pump CABG patients.

CONCLUSION: Off-pump CABG avoids the risks of cardiopulmonary bypass and the systemic inflammatory response it elicits. A substantially lower need for postoperative blood transfusions and a trend towards a lower hemorrhage-related re-exploration rate suggests that Off-pump CABG is a safe revascularization option.

ABSTRACT 141

OUTCOME OF PATCH ANGIOPLASTY FOR ISOLATED LEFT CORONARY OSTIAL STENOSIS

Chan-Young Na, Sam Se Oh, Man Jong Baek, Soo Cheol Kim, In Seok Choi, Woong-Han Kim, Cheong Lim, Song Wok Whang, Young Kwang Park, Chong Whan Kim
Department of Thoracic & Cardiovascular Surgery, Sejong General Hospital, Pucheon, Korea

BACKGROUND: Patch angioplasty for coronary ostial stenosis is assumed to be an alternative approach to coronary artery bypass grafting (CABG). The clinical features of isolated coronary ostial stenosis, postoperative complications and follow-up angiographic results have not been well studied.

METHODS: We retrospectively studied 29 patients (male: female = 6 : 23, age =33-79 year (mean = 50.0 year) who underwent surgical angioplasty for isolated left coronary ostial stenosis using patch (26 fresh autopericardium, 2 saphenous vein, and 1 bovine pericardium) during the period of March 1990 and October 2002. Repeat coronary angiography (17 patients) and echocardiography (29 patients) were performed. Aortic regurgitation (AR) was evaluated semiquantitatively (Grade I - Grade IV).

RESULTS: There were 2 deaths after surgical angioplasty. One death was due to acute coronary artery dissection perioperatively, and the second was due to traumatic pancreatitis at postoperative 10 months. Follow-up was completed in all patients (1-134months, mean = 53 months). Angina occurred in 5 patients and the remaining 24 patients were symptom-free. Repeat coronary angiography in 5 symptomatic patients showed that 3 patients had 1 distal patch stenosis, 1 ostial stenosis in Takayasu's arteritis, 1 left main stenosis and 2 patients had widely patent ostium with excellent run-off. First distal patch stenosed patient was received percutaneous coronary angioplasty. Second symptomatic Takayasu's arteritis patient was managed with steroid. Third left main stenosis patient received off-pump CABG at postoperative 6 months. Fourth symptomatic patient was proven to have coronary spasm by ergonovine test, and AR increased in the fifth symptomatic patient (Grade II - III) with patent ostium.

CONCLUSION: Surgical angioplasty may be feasible and alternative operative method to CABG for isolated left coronary ostial stenosis. It should, however, be noted that postoperative AR develop and/or increase. Further investigation is need to evaluate the clinical significance of AR

ABSTRACT 142

CABROL TECHNIQUE APPLICATION IN CORONARY ARTERY BYPASS GRAFTING USING RADIAL ARTERY

Chan-Young Na, Woong-Han Kim, Sam Se Oh, Soo Cheol Kim, Man Jong Baek, Cheong Lim, In Seok Choi, Song Wok Whang, Young Kwang Park, Chong Whan Kim

Department of Thoracic & Cardiovascular Surgery, Sejong General Hospital, Pucheon, Korea

INTRODUCTION: In coronary artery bypass grafting (CABG), multiple proximal anastomosis may increase the risk of cerebral embolism (air, debris) and aortic injury (dissection, pseudoaneurysm). Radial artery (RA) has no intraluminal valve such as saphenous vein (SV). Cabrol technique using RA graft can reduce the number of proximal anastomosis in CABG. We report Cabrol technique for proximal anastomosis in CABG with RA graft.

Technique:

1. Left coronary artery -distal anastomosis with RA graft.
2. Cabrol type proximal anastomosis with RA graft (side to side).
3. Removal of air and debris through proximal end of RA graft and clamping.
4. Right coronary artery - distal anastomosis with SV graft
5. RA graft to SV graft anastomosis (end to end).

Advantages:

1. Effective use of graft length.
2. Effective removal of air and debris through proximal end of RA graft (reduce cerebral embolism)
3. Reduce number of ascending aorta manipulation.

ABSTRACT 143

**COSMETIC INCISION FOR SIMPLE CONGENITAL HEART DEFECTS
IN FEMALE PATIENTS**

Takashi Murakami, Masahiko Kuinose, Masami Takagaki, Eiichiro Inagaki
Dept. of Cardiovascular Surgery, Iwakuni National Hospital, Iwakuni, Japan

Among the cosmetic approaches for correction of simple congenital cardiac, the most popular one is small vertical skin incision and a partial lower sternotomy. Our concern is that the vertical skin incision for female, even the small one, is still visible while wearing the bra. We used the limited transverse incision, Mt. Fuji-like incision, with lower sternotomy for juvenile and adult female patients. Cases: Two female patients, one with atrial septal defect (ASD) and one with ventricular septal defect (VSD), underwent the operation through this incision. Small transverse horizontal line was made at the height of bra on the sternum. Then the both end of line was directed caudal gradually about 4 cm each, making a small mountain-like shape. Partial lower sternotomy was made to approach the heart. Operative scar was visible only 4 cm at the mid portion on the sternum and even that portion can be covered by the bra. Other portion of incision line was covered by the breast when it was well developed, being cosmetically appealing.

ABSTRACT 144

A SELF RETAINING ATRIAL SPREADER FOR MINIMALLY INVASIVE AND ROBOTICALLY-ASSISTED INTRACARDIAC OPERATIONS

Hitendu Dave 1, Jurg Grunenfelder 1, Peter Zollinger 2, Marko Turina 1, Gregor Zund 1

1. Clinic for Cardiovascular Surgery, University Hospital, Zurich, Switzerland.

2. Department of Mechanical Engineering, University Hospital, Zurich, Switzerland

OBJECTIVE : To develop a low-profile self retaining atrial spreader to facilitate minimally invasive and robotically-assisted ASD closure.

METHODS: A device was created using two 10mm broad strips of malleable stainless steel which were connected on both sides by simple hinges. Multiple pairs of broad blunt hooks were made on one edge of the device, as to allow better grip of the tissue. The device, which is completely collapsible, can be introduced into the thorax through a 12 mm standard port. In the non-compressed state the device opens to around 5 cm. Various lengths of the device from 11 cm to 4 cm were created. The device positioning was performed on an explanted pig heart and in a closed chest pig model.

RESULTS: The spreader was successfully introduced through 12mm ports and could spread and self-retain the standard right atriotomy, giving good exposure of all intra-atrial landmarks. The atrial spreading was adequate and secure to allow free movement of minimally invasive instruments.

CONCLUSION: This device is a useful tool for spreading the right atriotomy, thus obviating the need for stay sutures which can be cumbersome to place in minimally invasive and robotically-assisted approaches. Its use simplifies and expedites procedures like ASD closure.

ABSTRACT 145

COMPUTATIONAL CORONARY FLOW DYNAMICS

Evangelos Boutsianis 3 ,Hitendu Dave 1, Jurg Grunenfelder 1, Thomas Frauenfelder 2, Vincent Butty 3, Yiannis Ventikos 3 , Simon Wildermuth 2, Dimos Poulidakos 3, Marko Turina 1, Gregor Zund 1

1 Clinic for Cardiovascular Surgery,

2 Department of Radiology, University Hospital Zurich, Switzerland

3 LTNT, Swiss Federal Institute of Technology, Zurich, Switzerland

STATEMENT OF PURPOSE: Modern paradigm of surgical planning involves use of computational tools to construct and evaluate combined anatomic/physiologic models, thus improving the accuracy and the consistency of therapy. We simulated coronary flow using computational haemodynamic models.

MATERIALS & METHODS: The coronaries of explanted porcine hearts were perfused with 4% formaldehyde at physiological pressures. Omnipaque dye added to lead/rubber solution (Ratio 1:25), was used to cast the coronary arterial tree. CT sections of this model were used to reconstruct the 3-D coronary arterial geometry; which in turn was used to generate a volumetric tetrahedral mesh of approximately 600,000 elements. The unsteady equations of momentum and mass conservation were numerically solved.

RESULTS: The computational simulations yielded a wealth of quantitative information, including pressure and wall shear stress distributions, bifurcation mass flow rates and detailed velocity profiles (Figure 1). The variability of these quantities within the heart cycle was investigated at a temporal resolution of 1/100 second.

CONCLUSION: Such computational tools along with the possibility of having MDCT or MR based noninvasive coronary images could enable objective quantification of the effects of stenosis on the distal flow and pressure and thus aid in effective surgical/interventional planning. Additionally, it could also enhance our insight into coronary pathogenesis.

ABSTRACT 146

MITRAL AND TRICUSPIDAL VALVES SURGERY THROUGH AN ANTERIOR MINI THORACOTOMY

S. Djoshibaev, K. Urmanbetov, A. Sheraliev, U. Khalikov, A. Jumanazarov, J. Sheishenov.

Dept. of Cardiac Surgery, National Centre of Cardiology, Bishkek-Kyrgyzstan

OBJECTIVE: This report outlines the procedures and technical aids used performing mini thoracotomy in a series of 87 patients.

METHODS: Right anterior mini thoracotomy incision (to 10 cm) is made, using the inframammary groove in female patients. The chest is entered in the 4 (63) or 3 (24) intercostals space. The pericardium is then opened longitudinally. The aorta (52) or the left femoral artery (35) is cannulated, followed by the vena cava separately (58) or the dextra atrium of one cannules (27). CPB with mild hypothermia (32 C) is instituted. Access to the mitral valve it is carried out through the right atrium and the atrioseptal a partition at 58 and through a wall of the left auricle at 27 patients.

RESULTS: Mean CPB and ACC time were 78, 5 - 9, 5 and 53, 5-8, 5 minutes respectively. By all patients undergoing MV replacement and 20 patients TV annuloplastics. Removal of a tromb in the left auricle 13 and radio-frequency isolation pulmonary veins 23 patient. Extubation was carried out within the fifth hour. All patients were written out home during 7-10 days without complications.

CONCLUSIONS: We suggest that the technique of mitral and tricuspidal valve repair through the right anterior mini thoracotomy is a suitable alternative to that through a median sternotomy. The thoracotomy approach is safe and efficacious, and offers good exposure. The cosmetic result is superior to that of median sternotomy.

ABSTRACT 147

SURGICAL TECHNIQUE FOR THE CORONARY ANEURYSM

Yuji Takeda*, Naoki Minato, Kazuhisa Rikitake, Yuji Katayama, Tomoki Shimokawa, Manabu Itoh
Dept. of Cardiovascular Surgery, Fukuoka Tokushukai hospital, Fukuoka, Japan.

Two successful cases of the surgical treatment for the coronary aneurysm (non-Kawasaki disease) were reported. Our preferred technique is ligation of the coronary aneurysm and coronary arterial bypass grafting (CABG) to the distal portion of the aneurysm.

The first case had a stenosis on the left anterior descending artery (LAD) and had an aneurysm on the left circumflex artery (Cx). Ligation of the Cx. aneurysm was done subsequent to the double vessel CABG (LITA-LAD and SVG-Cx.) under the cardioplegic cardiac arrest.

The second case had aneurysms on both the LAD and the Cx. After CABG (LITA-LAD and SVG-Cx.) were performed, ligations were done under the on-pump beating heart. Postoperative course has been uneventful in both cases, now at 5 and 2 years after operation, respectively. With these experiences, we are now confident that this technique has an excellent mid-term durability and may be done in the most of cases under off pump beating heart using currently available devices.

ABSTRACT 148

DOES ROBOTIC TECHNOLOGY MAKE MINIMALLY INVASIVE CARDIAC SURGERY TOO EXPENSIVE? A HOSPITAL COST ANALYSIS OF ROBOTIC AND CONVENTIONAL TECHNIQUES

Jeffrey A. Morgan, MD, Barbara A. Thornton, MS, Karen W. Hollingsworth, BS, Nicholas J. Colletti, BS, Takushi Kohmoto, MD, Aftab R. Kherani, MD, Deon W. Vigilance, MD, Faisal H. Cheema, MD, Mauricio J. Garrido, MD, Yoshifumi Naka, MD, Eric A. Rose, MD, Craig R. Smith, MD, Mehmet C. Oz, MD, Michael Argenziano, MD
Division of Cardiothoracic Surgery, College of Physicians and Surgeons, Columbia University, New York, NY

OBJECTIVE: While potential benefits of robotically assisted cardiac surgery include decreased morbidity and improved recovery, some have suggested a prohibitively high cost. This study was undertaken to compare the actual hospital costs of open and robotically assisted cardiac procedures.

METHODS: Atrial septal defect (ASD) or mitral valve repair (MVr) were performed by sternotomy or minithoracotomy (OPEN, n=68), or with robotic assistance (ROBO, n=30) using the Da Vinci system (Intuitive Surgical, Mountain View, CA).

RESULTS: Intraoperative cost was higher for robotic ASD (p=0.054) and robotic MVr (p=0.025) as compared to open. However, there was no significant difference in total cost of robotic versus open procedures (table).

	Total Cost	Operative Cost	Postoperative Cost
ASD OPEN	28625 +/- 15694	12444 +/- 5747	12367 +/- 8571
ASD ROBO	27400 +/- 10221	16264 +/- 5780	11358 +/- 6430
p	0.794	0.054	0.707
MVr OPEN	37351 +/- 22066	16611 +/- 5540	13019 +/- 6818
MVr ROBO	34800 +/- 12313	20549 +/- 4079	11539 +/- 10619
p	0.681	0.025	0.594

CONCLUSIONS: Beyond the initial capital investment associated with robotic technology, robotic surgery does not increase total hospital cost. While intraoperative costs are higher for robotic procedures, these are offset by a less costly postoperative course. This may be secondary to a trend toward decreased ICU and hospital stay for robotic patients. Thus, it is possible that the benefits of minimally invasive surgery may justify investment in this technology.

ABSTRACT 149

SUTURELESS MITRAL VALVE REPAIR USING NITINOL CLIP TECHNOLOGY

L. Aklog, W. Nifong, R. Hebler, T. Galbraith, F. Realyvasquez, R. Chitwood
Mount Sinai Medical Center, New York, NY, USA

OBJECTIVE: Technical challenges continue to limit minimally-invasive mitral valve repair (MVP). We hypothesized that nitinol clip (NC) technology could facilitate various components of MVP.

METHODS: MVP was performed using self-closing NC's (Coalescent Surgical, Sunnyvale, CA) in isolated porcine hearts (n=14), chronic sheep (n=33) and calves (n=10). NC's were compared to suture for anterior leaflet (AL) repairs in the isolated hearts at 250 mm Hg. AL repair (n=10) or prosthetic annuloplasty (PA) (13 open, 10 robotic) was then performed in sheep to assess clip utilization and optimize clip design. Finally, MVP was performed in 10 calves (45-65 kg), using a stable clip design, including isolated PA (n=2), bileaflet repair (n=2) and combined posterior leaflet repair and PA (n=6). Follow-up included serial echocardiography, radiographic and histologic analysis at 1 (n=7), 3 (n=7) and 6 (n=6) months.

RESULTS: In bench testing, all clips and AL repairs remained intact. All repairs were intact and all PA's were securely attached at sacrifice. Gross and histologic evidence of leaflet healing and neointimal coverage of prosthetic material was confirmed in all animals. Echocardiography revealed no more than mild central regurgitation in any animal.

CONCLUSION: Sutureless MVP using nitinol clip technology can be performed expeditiously with good functional and histologic results. By eliminating knot-tying and suture management, this technology has the potential to facilitate MVP.

ABSTRACT 150

**INTEGRATED HYBRID CORONARY REVASCULARISATION :
A COST AND RESOURCE OUTCOME ANALYSIS IN HIGH-RISK
PATIENTS**

Hebsgaard K.P., Whitman G.R., Bonanomi G., Kim Y., Saul M.I, Cohen H.A.,
Zenati M.A.

Divisions of Cardiothoracic Surgery, School of Nursing, Biomedical Informatics
and Cardiology, Univ. of Pittsburgh, PA, USA

BACKGROUND: Integrated Hybrid Coronary Revascularisation (ICR) combines minimally invasive coronary bypass and angioplasty for patients with multivessel coronary artery disease. Encouraging clinical outcomes of the ICR approach have been reported, but little on the resource utilization (RU) outcome. Our goal was to evaluate the cost of ICR compared to conventional coronary artery surgery (CABG) in high-risk patients.

METHODS AND RESULTS: A retrospective cohort study design was used. Index hospital, one month, six month and twelve month post hospital follow up RU and costs between high risk patients undergoing ICR (N=28) and a matched CABG control group (N=41) were analyzed. RU included length of stay (LOS), readmission, outpatient visits and cost). Groups were comparable on demographic and clinical variables, but different regarding: age (69.6 vs 59.4 years; $p=.0001$), ejection fraction (44.4% vs 53.2%, $p = .002$), Parsonnet scores (14 vs 6.2; $p=.001$), preoperative cerebrovascular accidents (35.7% vs 7.3%; $p=.003$) and chronic obstructive pulmonary disease (46.4% vs 7.3%, $p=.0001$). LOS was shorter for ICR and no differences found in readmissions or costs throughout the first postoperative year. At one year aggregated costs of ICR and CABG were comparable (19934\$ vs. 21481\$, $p=0.12$).

CONCLUSION: ICR, although a 2-stage procedure requiring costly coronary stents, is a cost-effective or at least not a more costly procedure than conventional CABG for high risk patients.

ABSTRACT 151

VALIDATION OF THE BUTTERFLY TRANSIT TIME FLOW METER

Jeffrey Rentz, Patty Meldrum, Shreekanth Karwande, Brian Whisenant
University of Utah, Salt Lake City, Utah, USA

INTRODUCTION: The Transit Time Flow Meter (TTFM) probe uses ultrasound to measure the time difference between waves traveling against the normal flow and in the same direction of normal flow. Our objective was to validate the TTFM by comparing its results to postoperative angiograms.

METHODS: The TTFM was applied to all off-pump coronary grafts performed by a single surgeon. All patients had a coronary angiogram before discharge. The surgeon was blinded to TTFM results intra-operatively.

RESULTS: Forty-seven grafts were measured in 19 patients between 8/01 and 10/02. Six of 47 grafts (12.8%) were compromised according to the angiograms and all were identified by the TTFM. Four of six grafts had an anastomotic stenosis less than 50%. The TTFM showed patency in 35 grafts and the angiogram correlated for all 35. The TTFM contended that six grafts were compromised but the postoperative angiogram demonstrated patency. Overall, the sensitivity was 85% (35/41), specificity was 100% (6/6), positive predictive value was 100% (35/35) and the negative predictive value was 50% (6/12).

CONCLUSION: The Butterfly Transit Time Flow Meter is extremely sensitive for identifying compromised bypass grafts intra-operatively.

ABSTRACT 152

CONGENITAL FISTULA BETWEEN LEFT INTERNAL MAMMARY ARTERY (LIMA) AND PULMONARY ARTERY: CAUSE OF LIMA BYPASS OCCLUSION?

Friedrich-Christian Riess, Claas Lehmann, Christine Loewer, Joachim Schofer, Niels Bleese. Albertinen Hospital, Hamburg, Germany

OBJECTIVES: Angiography of the internal mammary arteries (IMA) prior to coronary artery bypass grafting (CABG) in order to assess suitability of the vessel as graft is not a standard procedure during diagnostic heart catheterization.

MATERIAL AND METHODS: We report on a 49 years old patient with severe aortic valve regurgitation and coronary artery disease. PTCA and LAD stenting had been performed because of a significant proximal LAD lesion. Repeated coronary angiogram 3 months later revealed a patent stent, but severe sclerosis up to a 40% stenosis of the LAD prior to the area of stenting. The patient was operated with standard cardiopulmonary bypass (CPB). A mechanical aortic valve was implanted. Despite of the non significant stenosis the LAD was bypassed with a LIMA-graft for prophylactic reasons.

RESULTS: Operation and postoperative course was uneventful. However, two years after surgery a control angiogram revealed a LIMA-bypass occlusion and a large congenital fistula deriving from the proximal part of the left IMA to the pulmonary artery. Diminished flow in the IMA-bypass due to the fistula in combination with a non significant proximal LAD stenosis might be the reasons for IMA-bypass occlusion. The fistula was occluded by coils during an interventional cardiological procedure.

CONCLUSIONS: A fistula between IMA and pulmonary artery is a seldom congenital defect but may be one reason for IMA-bypass occlusion. Therefore, angiography of the IMA should be mandatory in all cases of arterial coronary revascularization using IMA bypasses in order to detect malformations preoperatively.

ABSTRACT 153

LESS ADHESION FORMATION AFTER CARDIAC SURGERY BY CHYMASE INHIBITOR - A NEW STRATEGY TOWARD SAFER REOPERATIONS

Yoshiharu Soga a, Shinji Takai b, Tadaaki Koyama a, Yukiko Okamoto b, Tadashi Ikeda a, Kazunobu Nishimura a, Mizuo Miyazaki b, Masashi Komeda a
a. Department of Cardiovascular Surgery, Kyoto University
b. Department of Pharmacology, Osaka Medical College, Japan

OBJECTIVE: Chymase is released from mast cells, which are associated with adhesion formation. Chymase activates transforming growth factor-beta1 (TGF-beta1), which promotes tissue fibrosis. We studied whether a chymase inhibitor prevents postoperative cardiac adhesions.

METHODS: In sixty-six hamsters the epicardium was abraded, and either chymase inhibitor (C-Group) or placebo (P-Group) was injected into the left thoracic cavity.

RESULTS: The cardiac chymase activity and TGF-beta1 level 3 days postoperatively were lower in C-Group than P-Group (45.8 +/- 18.7 vs. 79.7 +/- 13.7 microU/mg protein, $p < 0.025$, 15.6 +/- 6.5 vs. 33.2 +/- 9.8 microgram/ml, $p < 0.01$, respectively). The density of mast cells was higher in P-Group, and this value was suppressed for 60% in C-Group. The adhesion scores (macro- and micro-scopic, 2 weeks postoperatively) were lower in C-Group than P-Group (1.3 +/- 1.3 vs. 3.0 +/- 1.1, $p < 0.01$).

CONCLUSION: Chymase inhibitor may be useful to attenuate postoperative adhesions.

ABSTRACT 154

THE BENEFITS OF SKELETONIZED BILATERAL INTERNAL THORACIC ARTERY IN CORONARY ARTERY BYPASS GRAFTING

Etsuro Suenaga, Hisao Suda, Shinya Higuchi, Noritoshi Minematsu
Nagasaki Kouseikai Hospital, Nagasaki, Japan

BACKGROUND: The purpose of this study is to evaluate the advantages of skeletonized bilateral internal thoracic artery (ITA) over the pedicled bilateral ITA in coronary artery bypass grafting (CABG).

METHODS: One hundred and seven patients underwent CABG using bilateral ITA. In Group-I (n=32), the ITAs were harvested with the skeletonization technique. In Group-II (n=75), they were harvested with pedicle. On-pump CABG was performed in this study.

RESULTS: There were no events of operative death or wound infection. The average number of grafts and aortic cross-clamp time were similar in both groups. Total operation time was shorter in Group-I than in Group-II (295±51 minutes vs 326±51 minutes, $p<0.01$). Postoperative first 12-hour blood accumulation from the chest tubes was less in Group-I than in Group-II (248±159ml vs 479±255ml, $p<0.01$). The ratio of freedom from blood transfusion was lower in Group-I than in Group-II (53% vs 72%, $p<0.01$).

CONCLUSION: The use of skeletonized bilateral ITAs was more beneficial and less invasive than that of pedicled bilateral ITAs in CABG.

ABSTRACT 155

**CAN LEFT VENTRICULAR ASSIST DEVICES BE SAFELY
IMPLANTED WITHOUT CARDIOPULMONARY BYPASS SUPPORT?**

Valentino Piacentino III, PhD, Janice Jones, CRNP, Dipin Gupta, MD, Carol A. Fisher, BA, Theresa Hollander, RN, PhD, Arun K. Singhal, MD, PhD, Mahender Macha, MD, James B. McClurken, MD, Satoshi Furukawa, MD. Temple University Hospital, Philadelphia, PA, U.S.A.

Given the encouraging results of the R.E.M.A.T.C.H. Trial, LVADs now hold the potential for great advances in treatment of end-stage HF. However, early mortality remains high, and improvement of implantation techniques and post-operative management are critical for LVADs to realize their true potential as life-saving devices. Until now, implantation of LVADs has required cardiopulmonary bypass (CPB), which may exacerbate multi-organ dysfunction and RV failure. Our goal was to determine 1) whether LVADs could be safely implanted without CPB support and 2) any potential benefit in intraoperative blood product usage. Eight patients (mean age, 57 years) received either a Thoratec or Heartmate LVAD with [OnPump, (n=4)] or without [OffPump, (n=4)] intraoperative CPB. All patients were inotrope-dependent in end-stage HF. There were no intraoperative deaths. Intraoperative blood product requirements for OffPump were significantly less ($p<0.05$) than OnPump (1.7 ± 0.6 vs. 3.6 ± 0.7 units packed red cells). These preliminary results prove that implantation of LVADs without CPB support is safe. This refinement in implantation technique may further broaden the successful application of LVADs to older and sicker patients with HF. Furthermore, the decreased blood products usage may be advantageous to patients receiving a LVAD as a bridge to cardiac transplantation.

ABSTRACT 156

HYBRID SURGICAL REVASCULARIZATION: “CABG” OF THE FUTURE

Michael Grosso, MD

St. Francis Hospital / Heart Center; Wilmington, Delaware, USA

The treatment of coronary artery disease is changing at an exponential pace. Increasingly, the surgeon is asked to perform standard coronary artery bypass grafting (CABG) only after all percutaneous interventions have been exhausted.

Short of those patients with left main disease, few patients are referred for CABG who have not already had previous coronary percutaneous intervention (often multiple times). By then however, the native CAD has usually progressed to the point that complete revascularization is often technically impossible or exceedingly risky.

Alternative surgical revascularization strategies must be developed for these increasingly challenging situations. Hybrid CABG must encompass more than just LIMA to LAD plus angioplasty. We believe transmyocardial laser revascularization (TMR) offers the surgeon such a technique.

Our experience with TMR in 218 patients supports this approach. Holmium: YAG laser (CardioGenesis Corp., Foothill Ranch, CA) was used alone or in conjunction with standard CABG to obtain complete revascularization despite extensive native CAD. Careful patient and target vessel selection optimized outcomes with low operative mortality (2.2%: CABG+TMR off pump. Follow-up (0.1- 3.2 years, mean 1.2 years) revealed sustained angina relief (82% - Class 1) and excellent intermediate term survival. TMR allowed complete revascularization to be achieved at low risk with excellent results.

In addition, we believe TMR will serve as a primer or scaffolding for future surgical techniques such as gene therapy, growth/angiogenesis factor application and cell transplantation.

ABSTRACT 157

AVOIDING AIR EMBOLISM WITH CARDIO-PULMONARY BYPASS

David Jayakar MD, Jack Copeland DM

OBJECTIVE: Delayed air embolism is common after open heart surgery. Air embolism after open heart surgery are due to immediate causes (<20 mins from cross-clamp removal – due to retained intra-cardiac air) and delayed causes (>20 mins from cross-clamp removal – due to air entrapped in pulmonary veins). Delayed air embolism is of grave clinical consequence. Right ventricular dysfunction and neurological problems have been linked to delayed air embolism. We eliminated delayed air embolism by compressing the apex of both lungs while on cardio-pulmonary bypass during open cardiac surgeries.

METHODS: We open the chest using a midline sternotomy and for any open cardiac (non-CABG) procedure. We then proceed to open the pleura on both sides of the chest. Once we initiate bypass and the ventilation had stopped, we place two wet laparotomy pads on the superior and anterior aspect of both lungs to compress the parenchyma posteriorly. By collapsing the lung we squeeze the parenchyma so no air can get into the pulmonary venous system. We remove the sponges when the cross clamp is removed and do the standard de-airing procedure.

RESULTS: Using the sponge lung compression technique, 20 consecutive patients were studied. 19 patients did not have any significant delayed air embolism. In comparison to data presented by Tingleff¹ 13 of 15 patients studied had significant air by TEE and the total duration of air embolism lasted as much as 28 minutes after terminating bypass.

CONCLUSIONS: The sponge compression technique has completely abolished the incidence of delayed air embolism. This would entail in improving right ventricular and cerebral function post-bypass.

Reference:

1) Tingleff J, Joyce FS, Pettersson G.: Intraoperative Echocardiographic Study of Air Embolism during cardiac operations. Ann. Thorac. Surg 1995;60:673-77.

POSTER
PRESENTATIONS

ABSTRACT 158

**CORONARY REVASCULARIZATION IN HIGH RISK PATIENTS –
DRAMATIC IMPROVEMENT IN NEUROLOGICAL OUTCOMES
USING OPCABG**

Jayakar DV, Stephenson G, Jeevanandam V.
University of Chicago Hospitals, Chicago, IL, USA

BACKGROUND: The benefits of off-pump coronary artery bypass (OPCAB) remain undefined. We sought to identify a patient population that might benefit from this technique.

METHODS: All 225 patients undergoing CABG (on and off pump) between 3/2000 and 3/2001 were reviewed. Analyzed risk factors included recent CVA, EF<30%, acute MI, COPD, active smoking, obesity, renal dysfunction, age > 75 years, liver dysfunction and hemodynamic instability. One point was assigned per factor. Only patients with a score of 2 or higher were included in the study.

RESULTS: 85 OPCABG (risk score 3.4) and 83 pump CABG (3.3) were done during this time period. The numbers of grafts, incidence of perioperative MI and completeness of revascularization were similar in both groups. Length of hospital and ICU stay, use of inotropes and IABP, and time to extubation were better in the OPCABG group. We had one death (1.1% early mortality), and no major neurological events in the OPCABG group vs (4.8% early mortality, $p<.01$), and 4 (5%, $p<.05$) major neurological event in the pump CABG group. Four patients (4.7%) were converted to pump CABG due to hemodynamic instability.

CONCLUSIONS: Avoiding cardiopulmonary bypass significantly decreases neurological morbidity and mortality in this group of patients without affecting the quality of revascularization. Hence, OPCAB is the optimal method of surgical revascularization for high risk patients.

ABSTRACT 159

**OFF-PUMP EPICARDIAL ATRIAL FIBRILLATION SURGERY
UTILIZING A NOVEL BIPOLAR RADIOFREQUENCY SYSTEM**

Deon W. Vigilance, Mauricio Garrido, Mathew Williams, Elaine Wan, Ann Zeidner, Jennifer Casher, Karl Zheng, Amanda Beck, Aftab R. Kherani, Jeffrey A. Morgan, Faisal H. Cheema, Yoshifumi Naka, Mehmet C. Oz, Michael Argenziano
Division of Cardiothoracic Surgery, Columbia University, College of Physicians and Surgeons, New York, NY

BACKGROUND: The current standard for surgical treatment of atrial fibrillation involves endocardial ablation with cardiopulmonary bypass and atriotomy. This study was undertaken to evaluate a novel radiofrequency (RF)-enabled clamp system designed to create transmural lesions on the beating heart epicardially using bipolar RF.

METHODS: A set of differently shaped clamps modified to deliver bipolar RF energy (Boston Scientific Corporation) were used to create a series of lesions in a beating heart canine model. The pulmonary veins and atrial appendages of six dogs were electrically isolated using bipolar RF energy. The right and left atrial appendages served as controls for the right and left pulmonary veins, respectively. Temperature controlled RF energy was delivered to maintain a tissue temperature of 80°C for 15 seconds. Electrical isolation was assessed acutely and after 4 weeks by a bipolar pacing protocol.

RESULTS: A total of 24 circumferential lesions were created. By pacing analysis, 100% of these lesions were electrically isolated acutely and 95% four weeks later. At four weeks, 92% of lesions were transmural by histologic analysis, and 96% demonstrated endocardial continuity.

CONCLUSION: Bipolar radiofrequency ablation utilizing a novel bipolar RF clamp device results in electrical isolation and histologic transmural in an off-pump epicardial model.

ABSTRACT 160

BIPOLAR RF ABLATION WITH TRANSMURALITY FEEDBACK FOR THE SURGICAL MAZE PROCEDURE

Alison A. Lutterman-2, Chad E. Hamner MD-1, D. Dean Potter MD-1, Thoralf M. Sundt MD-1, Hartzell V. Schaff MD-1, David E. Francischelli-2
1. Mayo Clinic, Rochester, MN
2. Medtronic Inc., Minneapolis, MN

BACKGROUND: Radiofrequency ablation (RFA) has been used to replicate surgical scars of the Maze procedure. This study aimed to demonstrate an irrigated, bipolar RFA device could effectively create Maze scars using a transmural feedback program.

METHODS: A complete Maze-III lesion pattern was created ex vivo on eleven fresh porcine hearts with the Medtronic Cardioblate BP Surgical Ablation System. Adequate jaw-closure force was applied to ensure tissue/electrode contact. A proprietary feedback and control algorithm monitored tissue impedance in real-time for all lesions, and ablation was terminated when lesions were deemed transmural by the algorithm. After hearts were stained with 1% TTC, lesions were cross-sectioned at 5mm intervals and grossly examined for transmural.

RESULTS: A total of 137 lesions, 24.1 ± 8.4 mm in length, were created on porcine atrial tissue. Average tissue thickness was 3.0 ± 1.7 mm (range 0.5 - 9.9mm). Cross-sectional examination revealed that 100% of lesions were transmural (n = 718).

CONCLUSIONS: These results indicate the Medtronic Cardioblate BP Surgical Ablation System reliably replicated the full Maze-III lesion pattern ex vivo on intact porcine atria with a 95% confidence that at least 98% of lesions are transmural. Additional in vivo studies are underway to further demonstrate efficacy and safety of this system.

ABSTRACT 161

TREATMENT OF INTERRUPTED AORTIC ARCH WITH EXTRAANATOMICAL BYPASS SIMULTANEOUS TO CORONARY ARTERY BYPASS GRAFTING AND AORTIC VALVE REPLACEMENT

Friedrich-Christian Riess, Matthias Danne, Jan-Hendrik Stripling, Heinz Bergmann, Niels Bleese, Albertinen Hospital, Hamburg, Germany

OBJECTIVE: We describe simultaneous treatment of an interrupted aortic arch, coronary artery bypass grafting (CABG), and aortic valve replacement (AVR) through median sternotomy.

MATERIAL AND METHODS: A 64 year old man (75 kg) showed progredient stress dyspnea and angina due to severe aortic valve regurgitation and coronary artery 3-vessel disease. Beside upper body arterial hypertension the patient showed pulseless extremities and hypoplasia of the legs. Preoperative MRT demonstrated an interrupted aortic arch directly after the origin of the left subclavian artery, and a calcified bicuspid aortic valve with severe regurgitation. The patient was operated using standard cardiopulmonary bypass (CPB) with cannulation of the ascending aorta and the right atrium, hypothermia (24.6°C), and blood cardioplegic arrest. Four aortocoronary vein grafts and pericardial aortic valve replacement were performed. Finally the posterior pericardium was opened and a 16 mm vascular prosthesis was anastomosed to the descending aorta during side clamping. The prosthesis was guided to the ascending aorta laterally to the right atrium passing between inferior vena cava and right inferior lung vein in order to obtain optimal placement.

RESULTS: The operation was carried out without complications, and the postoperative course was uneventful. MRT showed a competent aortic valve prosthesis, unobstructed flow through the extraanatomical bypass, and highly decreased collateral flow via the internal mammary arteries. Postoperatively both inguinal pulses were present and the patient was free of angina.

CONCLUSIONS: In the presence of an interrupted aortic arch an extraanatomical bypass between ascending and descending aorta can be performed safely and easily in addition to CABG and AVR through median sternotomy.

ABSTRACT 162

TOTAL ARTERIAL REVASCLARIZATION WITH AND WITHOUT CARDIOPULMONARY BYPASS

Marek A.Deja, Kazimierz Widenka, Marek Jasiński, Ryszard Bachowski,
Piotr Olszówka, Paweł Żurek, Roman Mrozek, Krzysztof S.Golba,
Stanisław Woś;
2nd Dept of Cardiac Surgery, Medical University of Silesia

AIM : To compare the early results of total arterial revascularization for multiple vessel disease performed with and without the use of CPB.

METHODS : Retrospective analysis of perioperative data of patients in who total arterial revascularization for multiple vessel coronary artery disease was performed with the use of CPB (92pts) and without CPB (55pts). Patient characteristics:

	OPCAB (n=55)	CPB (n=92)	p
Age	57±9	56±8	NS
Sex	47males (85%)	76males (83%)	NS
Unstable angina	2 (3.6%)	5 (5.4%)	NS
Acute MI	3 (5.5%)	3 (3.3%)	NS
EF	55±11%	52±13%	NS
Diabetes	10 (18%)	16 (21%)	NS
Previous stroke	3 (5.5%)	1 (1.1%)	NS

RESULTS : Perioperative data are presented in the table:

	OPCAB (n=55)	CPB (n=92)	
No of grafts	2.4±0.7	2.9±0.9	P=0.005
LITA	53 (96.4%)	92 (100%)	NS
RITA	22 (40%)	42 (46%)	NS
RA	42 (76%)	76 (83%)	NS
GEA	0 (0%)	2 (2.2%)	NS
Sequential grafts	14 (12%)	48 (23%)	P=0.024
CPB time -		67±21min	
X clamp time -		48±17min	
Conversion to CPB	1 (1.8%)		
Death (early/late)	0/0	0/1	NS
MI	2 (3.6%)	5 (5.4%)	NS
Low CO	1 (1.8%)	5 (5.4%)	NS
IABP	1 (1.8%)	6 (6.5%)	NS
Dopamine	10 (18%)	90 (97.8%)	P=0.001
Adrenaline	1 (1.8%)	12 (13%)	P=0.043

	OPCAB (n=55)	CPB (n=92)	
IPPV time	7.0±3.8h	9.5±4.4h	NS
Stroke	1 (TIA) (1.8%)	3 (3.3%)	NS

CONCLUSION : Total arterial revascularization for multiple vessel coronary artery disease is possible without CPB. We observe tendency to smoother postoperative course in patients operated without CPB. However they have on average less grafts placed and the lower number of sequential anastomoses performed.

ABSTRACT 163

EXCLUSIVE ARTERIAL OFF-PUMP REVASCULARISATION IN MULTIVESSEL DISEASE

Pierre Yves Etienne

Clinique St. Luc, Namur, Belgium

BACKGROUND : Arterial grafting is expected to decrease the rate of cardiac events after myocardial revascularisation. Anyway, few authors report the use of complex arterial procedures in off pump surgery.

METHODS: Between 4/2000 and 8/2002, all patients referred for myocardial revascularisation were operated on the beating heart including unstable patients. From those 392 patients, 200 (51%) underwent exclusive arterial revascularisation with use of bilateral internal mammary arteries (IMA), gastroepiploic arteries or radial arteries.

RESULTS: Sternotomy was used in 192 patients while MIDCAB in 8. Mean number of distal anastomoses was 3.5/pt (2-6). Conversion to cardiopulmonary bypass occurred in only 2 patients. Perioperative infarction rate reached 0.5% and hospital mortality 0.5% for an expected predicted mortality of 3.5% with the Euroscore. No patient suffered perioperative stroke. 1 patient underwent temporary mechanical assistance (6 days) for right ventricular failure. Follow up was 100% complete. 80% of the patients consented to a maximal stress test. At 1 year, actuarial survival was 96.4% and freedom from recurrent angina was 99.1%.

CONCLUSIONS: Complete revascularisation with complex arterial grafting is feasible on the beating heart with excellent immediate results and a very low rate of recurrent angina at 1 year.

ABSTRACT 164

THE USE OF SKELETONIZED INTERNAL THORACIC ARTERY (ITA)Etsuro Suenaga

Nagasaki Kouseikai Hospital, Nagasaki, Japan

BACKGROUND : The use of skeletonized internal thoracic artery (ITA) was reported to be technically and hemodynamically beneficial in coronary artery bypass grafting (CABG). The purpus of this study was to evaluate the impact of use of skeletenized ITA harvested by ultrasound scalpel compared with conventional pedicle ITA.

MATERIAL AND METHODS: Between January 2001 and October 2002, a total of 107 consecutive patients were underwent CABG using bilateral ITA. These patients were divided into two groups according to the ITA harvesting method. Group-I (N=32) IMA was harvested as skeletonized was compared with Group-II (n=75) conventional harvest in early operative result.

RESULTS: There was no operative death and wound infection in this series. There was no significant difference between two groups in preoperative patients' characteristics. There was no significant difference in average number of grafts (3.3 ± 1.1 in Group-I, 3.4 ± 0.6 in Group-II,) and aortic cross clamp time (74 ± 27 in group-I, 86 ± 28 in Group-II). Total operative time was significantly shorter in Group-I, 295 ± 51 minutes compared with Group-II, 326 ± 51 minutes ($P<0.01$). Bleeding 12 hours after operation was significant lower in Group-I, 248 ± 159 ml compared with Group-II, 479 ± 255 ml ($P<0.01$). Freedom from homologous blood transfusion was significant lower in Group-I, 53% compared with Group-II, 72% ($P<0.01$).

CONCLUSION: The use skeletenized ITA harvested by ultrasound scalpel was beneficial and less invasive to the patient by shorter operative time and lower postoperative bleeding.

ABSTRACT 165

VALVE SPARING RESECTION OF TWO TRICUSPID VALVE MYXOMAS

Friedrich-Christian Riess, Heinz Bergmann, Matthias Danne, Udo Helmchen, Jan-Hendrik Stripling, Niels Bleese
Albertinen Hospital, Hamburg, Germany

OBJECTIVE: Myxomas of the tricuspid valve are extremely rare. We report on two papillary myxomas, located at the anterior leaflet and the tricuspid annulus of the tricuspid valve.

MATERIAL AND METHODS: A 67 years old man was scheduled for coronary artery bypass grafting (CABG) because of angina due to a severe 2-vessel coronary artery disease. Preoperative MRT revealed two tumors (size: 2 - 3 cm each) at the anterior leaflet of the tricuspid valve, which was prolapsing into the right ventricle during diastole. Minor tricuspid valve regurgitation was detected. The patient was operated using standard cardiopulmonary bypass (CPB) with cardioplegic arrest and mild hypothermia (34°C). A left internal mammary artery jump bypass to LAD and diagonal branch was performed as well as a venous bypass to the marginal branch. The tumors were excised from the anterior leaflet of the tricuspid valve and the tricuspid annulus. The defect was closed with a continuous 5-0 monofilic suture of the anterior leaflet and creating a plicature of the tricuspid annulus.

RESULTS: Operative procedures were performed without complications. CBP time was 98 min and aortic cross clamp time 75 min. Postoperative MRT showed no tricuspid valve regurgitation, mean delta p of 1.0 mmHg and max delta p of 3.3 mmHg. Postoperative course was uneventful. The patient was discharged from hospital on the 10th postoperative day in good condition and was free of any recurrence during a follow up of 21 months. Histological examination revealed two papillary myxomas.

CONCLUSION: Two papillary myxomas of the anterior tricuspid leaflet and the tricuspid annulus were successfully removed and the tricuspid valve was preserved by valve reconstruction.

ABSTRACT 166

SURVIVAL AFTER SEVEN HOURS OF SUSTAINED VENTRICULAR FIBRILLATION WITH THE MICROMED DEBAKEY LVAD: A CASE REPORT

S. Salzberg, D.Bettex , A. Kadner, G. Zünd, M.Lachat, M.Turina
Clinic for Cardiovascular Surgery and Anaesthesiology,
University Hospital, Zurich, Switzerland

Patients with terminal heart failure are prone to develop malignant ventricular arrhythmias causing death if not treated immediately. We describe the case of a 61 year old patient on mechanical circulatory support as bridge to heart transplantation (MicroMed DeBakey LVAD, Houston, USA) following terminal heart failure due to valvular cardiomyopathy. After 52 days of LVAD support the patient was taken ill during his stay in a specialised rehabilitation clinic. After transfer to our clinic electrocardiography showed ventricular fibrillation in an ambulating, conscious and oligosymptomatic patient. Furthermore the patients pace-maker auto-diagnosis function (MedTronic InSync III, Minneapolis, USA) revealed a continuous pattern of ventricular fibrillation exceeding 7 hours. Absence of flow through the native left heart and impactment of the right ventricle were documented by echocardiography. After external defibrillation regular sequential paced heart rhythm with stable hemodynamics was restored. Left ventricular ejection and flow through the aortic valve was confirmed by echocardiography. Ventricular unloading through non pulstaile mechanical support seems to be enough for adequate pulmonary blood flow. This report demonstrates that the MicoMed DeBakey LVAD is able to generate sufficient blood flow for viable end-organ function and pulmonary perfusion in the absence of cardiac output.

ABSTRACT 167

THE CLAP CLASSIFICATION : AN INNOVATIVE METHOD FOR CLASSIFYING MITRAL VALVE PATHOLOGY AND REPAIRJeffrey H. Shuhaiber

University of Illinois, Chicago, Il, USA

OBJECTIVES: (1) To develop a universal classification in mitral valve surgery than currently available to all heart surgeons at any level of training.(2) to provide professionals with a valid and systematic method for describing the mitral valve morphology surgically and mode of repair.

METHODS: Review and critical analysis of the all published classifications for mitral valve disease and surgery exhibit many disadvantages and lack practical definition and usage. As more evidence that some of the inherent abnormalities of the mitral valve and mode of repair can be significant predictors of outcome in cardiac surgery the CLAP Classification becomes necessary. Each of the four valve structures (chordae, leaflets, annulus and papillary muscles) is substituted with a mathematical binary system for each structure

RESULTS : The Clap classification is reliable. Examples of how classification works includes two equations and tables transforming the published data for valve repair in a simplified manner. Mitral morphology score is CLAP- X denotes:

$$\text{CLAP} \sum_{f=0,1}^6 \{C+L+A+P\} \quad X \in \{0, 6\}$$

CLAP - Σ (binary numbers of each C, L, A and P) $X \in (0 - 6)$, Mitral repair score is CLAP X / Y where X denotes annuloplasty size and Y the summative score for the types of repair involved

CONCLUSIONS: The CLAP classification is a simple, accurate and comprehensive mitral valve pathology and mode of repair. It has a severity score that is proportional to the number ranging from 0 to 6. The classification allows better documentation valve pathology and repair together with prospect for future universalization of tabulating mitral valve repair data

ABSTRACT 168

A NEW DOPPLER DEVICE FOR OPTIMIZED VESSEL PUNCTURE

Alexander Kadner, MD; Sacha Salzberg, MD; Reto Stocker, MD;
Marko I Turina, MD, Mario Lachat, MD
Clinic for Cardiovascular Surgery, University Hospital Zurich, Zurich,
Switzerland

INTRODUCTION: Central venous catheters are mainly placed by the landmark method (LM) and complication rate can be up to 20%. A new doppler device was developed allowing for doppler guided vessel puncture (DGP).

MATERIAL AND METHODS: We prospectively studied 132 patients (age 51 ± 14 years, 87m / 41f) who required a central venous catheter at our institution. The doppler puncture set includes a doppler device (4MHz) providing an acoustic and optical signal allowing for differentiation of venous and arterial flow pattern.

RESULTS: Doppler guided central venous catheterization was performed in 39 routine cases (50%), 17 teaching cases, and 18 emergency cases w(23%) compared to 47 routine cases (87%), 4 teaching cases (7%) and 3 emergency cases (6%) in the LM group. Success rate was 68% (n=58) with the DGP versus 61% (n=33) by using LM. No complications were studied in 92, 3% of the doppler device performed cases versus 81% of the LMM group. A lower overall complication rate was observed in DGP group (7.7%) compared to the conventional LM group (19%), including hematoma (1.3% vs 3.7%), arterial puncture (0% vs 3.7%), hemothorax (0% vs 1.9%), and pneumothorax (2.6% vs 1.8%).

CONCLUSION: The new doppler vessel cathetrization device was safe and simple to apply with superior results and less complications compared to the conventional landmark method.

ABSTRACT 169

OFF-PUMP CORONARY BYPASS WITH RIGHT HEART SUPPORT FOR HEMODYNAMIC STABILITY PROVIDES A SAFE METHOD FOR ANASTOMOTIC ACCESS

Tea Acuff MD

Denton Regional Medical Center, Denton, TX, USA

BACKGROUND: Off-pump coronary artery bypass (OPCAB) decreases complications of cardiopulmonary bypass (CPB). Positioning the heart for anastomotic access may compromise hemodynamic stability and limit patient eligibility. Right heart support (RHS) augments left ventricle preload and provides stability, particularly for lateral and posterior target vessels. This study evaluated adverse outcomes of OPCAB utilizing RHS.

METHODS: Retrospective analysis of data between 2000 and 2002 compared Group 1 (n=106) OPCAB with RHS (A-Med Systems, Inc., West Sacramento, CA) and Group 2 (n=1482) OPCAB without RHS or Group 3 (n=106) computer-matched OPCAB without RHS. Demographic, preoperative, and outcome data including cardiac, neurologic, renal, pulmonary, and infection were compared.

RESULTS: Groups 1 and 2 showed no differences for mortality, overall complications, or any of 19 adverse outcomes. There were significant differences in preoperative variables. Comparing Group 1 with Group 3 showed no preoperative variable differences except NYHA class (p=0.01) and no significant differences in mortality (2/106, 1.9% versus 4/106, 3.8%), overall complication rate (18/106, 17.0% versus 33/206, 20.8%), or other adverse outcomes. Group 1 had a decreased length of stay (4.0±3.2 days versus 5.7±6.8; p=0.02) and ICU days (1.1±1.5 versus 2.2±3.9; p=0.007).

CONCLUSIONS: OPCAB with RHS is safe, with equivalent outcomes to OPCAB without RHS.

ABSTRACT 170

EXTRACORPOREAL MEMBRANE OXYGENATION PROVES EFFICIENT CIRCULATORY SUPPORT AFTER CARDIAC SURGERY IN INFANTS AND CHILDREN

A Chatzis, N Giannopoulos, A Tsoutsinos, P Zavaropoulos, G Sarris
Department of Pediatric and Congenital Cardiac Surgery
Onassis Cardiac Surgery Center, Athens, Greece

OBJECTIVE: Evaluation of postoperative extracorporeal membrane oxygenation (ECMO) support following procedures in children with congenital heart disease (CHD).

METHODS: Over a 5-year period (11/1997-11/2002) 10 patients age 5 days to 28.5 months (median 3 months) who underwent surgical procedures for CHD received postoperative mechanical support for failing cardiac function despite optimal medical therapy. In 3 patients ECMO was instituted in the operating room and in 7 this was introduced in the ICU 2-48 (median 20) hrs postoperatively. The circuit setup included right atrial venous drainage and left atrial decompression cannulae, with arterial return to the aortic root.

RESULTS: Three patients (30%) survived after 70 ± 36 hrs, while in the remaining 7 the procedure was abandoned after 109 ± 58 hrs of circulatory support. One of the survivors died 4 months later, unable to wean off from mechanical ventilation. The other two, remain well in NYHA class II.

CONCLUSIONS: In spite the adverse effects of ECMO, the methodology provided the necessary support and allowed the failing heart to recover in a number of patients where inotropic support alone proved inadequate.

ABSTRACT 171

SINGLE BICAVAL VENOUS CANNULA AND ATRIAL SPREADER FACILITATE TOTALLY ENDOSCOPIC ROBOTICALLY-ASSISTED ATRIAL SEPTAL DEFECT CLOSURE

Grunenfelder J (1), Reuthebuch O (1), Dave H. (1), Leskosek B (2), Lachat M (1), Turina M (1), Zund G (1)

1. Clinic for Cardiovascular Surgery, University Hospital Zurich, Zurich, Switzerland
2. Division of Surgical Research, University Hospital Zurich, Zurich, Switzerland

OBJECTIVE: We report of our initial experience with a newly designed atrial spreader and a peripherally inserted single bicaval venous cannula for totally endoscopic atrial septal defect closure.

METHODS: A computer-enhanced surgical telemanipulation system (DaVinci, Intuitive Surgical, USA) was used to perform totally endoscopic atrial septal defect closure in a sheep model (n=4, 60-92kg). A single 32F bicaval cannula (Aotec AG, Baar, Switzerland) was introduced through jugular vein and placed in venae cavae. Arterial cannula was inserted into carotid artery. Three robotic arms and two additional ports were placed. Heart was fibrillated, right atrium opened and atrial septum exposed with atrial spreader inserted through 12mm port. After intentional opening of septum, defect was sutured, atrium closed and heart externally defibrillated.

RESULTS: Mean CPB and fibrillation times were 207 ± 18 and 78 ± 12 minutes, respectively. Mean CPB flow was 3.87 ± 0.39 l/min or $97.7\% \pm 4.5\%$ of theoretical flow (3.97 ± 0.42 l/min) with snared venae cavae and vacuum assisted venous drainage of 0-20mmHg and mean central venous pressure of 9.5 ± 5.7 mmHg. Exposure and consecutive suturing of atrial septum defect was achieved in all animals. One animal could not be weaned from CPB.

CONCLUSION: A peripherally inserted single bicaval venous cannula demonstrates safe and efficient CPB flow patterns without obstructing surgical view. Exposure with atrial spreader allows for comfortable robotically-assisted suturing of atrial septal defects.

ABSTRACT 172

CHARACTERIZATION OF REMAINING CORONARY ARTERY MOTION AFTER OCTOPUS STABILIZATION

Philippe Cattin 1, Hitendu Dave 2, Juerg Gruenenfelder 2, Tobias Vancura 3, Gabor Szekely 1, Marko Turina 2, Gregor Zuend 2

1. Computer Vision Laboratory, ETH-Zurich, Switzerland

2. Clinic for Cardiovascular Surgery, University Hospital Zurich, Switzerland

3. PEL, ETH-Hoenggeberg, Switzerland

OBJECTIVE: To characterize remnant coronary artery motion observed in a pig beating heart after Octopus stabilization.

MATERIAL AND METHODS: A progressive scan B/W-camera (X/Y-plane) and a laser distance sensor (Z-plane) were positioned 10 cm above the LAD of a pig beating heart. Several ECG and blood pressure synchronized video sequences (10sec each; 50 frames/sec) of successive heart beats were acquired. Dopamine was used to modulate blood pressure.

RESULTS: Motion analysis of a LAD branching point, showed significant reduction of maximal excursion, speed of excursion and motion trajectory after Octopus stabilization.

LAD	Excursion	mean BP	HR
Unstabilized	7.2mm±0.3mm	55mmHg	83
with octopus	300um±6.4um	55mmHg	82
"	318um±8.4um	78mmHg	86
"	330um±8um	88mmHg	116

The excursion variability between consecutive cardiac cycles was 8.8um±/-7um. Variability between cycles minutes apart was 18um±/-12um. This technique enabled us to track in-plane movement of a surface landmark, over the entire cardiac cycle with a spatial resolution of ~10um.

CONCLUSION: Negligible variability in motion between consecutive cardiac cycles and characterization of the trajectory of the anastomotic site after stabilization could help in developing a motion cancellation method for a surgical robot.

ABSTRACT 173

PROGRAM DEVELOPMENT AND LEARNING CURVES IN ROBOTIC TOTALLY ENDOSCOPIC CORONARY ARTERY BYPASS GRAFTING

J. Bonatti 1, T. Schachner 1, N. Bonaros 1, O. Bernecker 1, O. Chevtchik 1, H. Ott 1, G. Friedrich 2, F. Weidinger 2, G. Laufer 1, Innsbruck University Hospital Departments of Cardiac Surgery¹ and Cardiology², Innsbruck, Austria

BACKGROUND : Totally endoscopic coronary artery bypass grafting (TECAB) using robotic techniques is an innovative procedure the introduction of which, may include increased mortality or morbidity. The aim of this report is to demonstrate the safe introduction of TECAB using a stepwise and modular approach.

METHODS : From 6/2001 to 10/2002 44 procedures were performed using the da VinciTM system. The following procedure modules were carried out in a stepwise manner: robotically assisted endoscopic LIMA harvesting and conventional CABG, MIDCAB, or OPCAB (n=18), robotically assisted LIMA to LAD anastomosis during conventional CABG (n=13), TECAB (n=12).

RESULTS : A significant learning curve was observed for LIMA take down time (65 (35-300) min), and total operative time in TECAB (435 (270-690) min.) The conversion rate in TECAB was 2/12. Intraoperative graft angiography showed a patent anastomosis in all cases of robotically assisted LIMA-anastomosis. Postoperative ventilation time and ICU stay were 13 (0-278) h and 24 (12-282) h respectively. There was no hospital mortality.

CONCLUSION : TECAB can be safely implemented into a heart surgery program. Learning curves are steep for LIMA harvesting and operative time in TECAB but less pronounced for anastomotic suturing. Long operative times translate into prolonged ICU stay but not into increased mortality.

ABSTRACT 174

INTRAOPERATIVE GRAFT ANGIOGRAPHY FOR QUALITY CONTROL OF ROBOTICALLY SUTURED LIMA GRAFTS

T. Schachner 1, N. Bonaros 1, M. Danzmayr 1, G. Friedrich 2, O. Pachinger 2, G. Laufer 1, J. Bonatti 1
Innsbruck University Hospital, Departments of Cardiac Surgery¹ and Cardiology², Innsbruck, Austria

BACKGROUND: Only few cases of totally endoscopic coronary artery bypass grafting have been performed worldwide and little is reported on the quality of the anastomoses. The aim of this study to investigate the quality of robotically sutured LIMA to LAD grafts by intraoperative angiography.

METHODS: LIMA to LAD bypass grafts were performed in 21 patients using the daVinci™ telemanipulation system. 11 anastomoses were performed via sternotomy and 10 endoscopically (median anastomotic time 35 (23-50) min). Graft angiography was conducted through femoral access with a 6F Judkins LIMA catheter using Visipaque™.

RESULTS: All anastomoses were patent on first inspection. Target vessel spasm was noted in 10 cases but it resolved after intraluminal injection of nitroglycerine. One anastomotic leak, one bleeding LIMA side branch and a local dissection of the LIMA caused by electrocautery were diagnosed. In all cases surgical repair was performed immediately. There was no perioperative myocardial ischemia and no hospital mortality.

CONCLUSION: The quality of LIMA to LAD grafts using robotic techniques is satisfying. Suturing of the anastomoses frequently leads to target vessel spasm but anastomotic patency is adequate. Bleeding from the anastomosis or graft can be detected by intraoperative angiography and repaired immediately.

ABSTRACT 22

A NOVEL APPROACH TO ACHIEVE BEATING HEART MAZE PROCEDURE

Gianluca Bonanomi, David Schwartzman, Marco Zenati
Division of Cardiothoracic Surgery, Atrial Arrhythmia Center,
University of Pittsburgh, Pittsburgh, PA, USA

AIM: To investigate the feasibility of a novel approach to achieve a lesion pattern similar to the left atrium component of the Maze III procedure in the beating heart using a bipolar clamping device and a purse string technique.

METHODS: Five healthy adult pigs (35-45 kg) underwent beating heart left atrium ablation through a median sternotomy. Ablation lesions were performed using radiofrequency energy delivered via a bipolar clamping hand piece. The design of the device enabled the complete encirclement of left and right pulmonary veins. The interconnecting lesions between the pulmonary veins and towards the mitral valve annulus were performed by introducing one jaw of the device into the heart through small purse strings. Appendectomy was performed utilizing a commercial stapling device.

RESULTS: A lesion pattern similar to the left atrium component of the Maze III procedure was deployed. The purse string technique could be performed safely and enabled the completion of the interconnecting lesions. All lesions produced conduction block. Pathological analysis revealed uniform, transmural lesions with no evidence of charring or barotrauma.

CONCLUSIONS: The use of a bipolar clamping device associated with the purse string technique enables a safe and effective left atrium Maze-like ablation on the beating heart.

INDEX OF AUTHORS

- A
- AbuSamra, Rafik 78
 Acocella, F. 39
 Acuff, Tea 234
 Acuña, Alejandro 72
 Aklog, L. 213
 Akpinar, Belhhan88, 110
 Albat, Bernard 67
 Alessi, C. 63
 AlZeerah , Masoud 43
 Anagnostopoulos, Constantine 133
 Antona , Carlo 38
 Antona, C. 39, 70
 Antona, Carlo 105
 Anzai, K. 74
 Argenziano, Michael212, 223
 Aronson, Solomon 92
 Asta, Angiolino 114
 Awwad, Nisa 58
- B
- Baan, Jan 195
 Bachowski, R. 134, 179
 Bachowski, Ryszard 226
 Baek, Man Jong205, 206
 Balzer, J. 68
 Bao, Yusheng 160
 Barberato, S. 104
 Bar-El, Yaron 166
 Barrera, Reyna L. 159
 Bauersfeld, U. 151
 Bavaria, Joseph E. 154, 171
 Beck, Amanda 223
 Beholz, Sven 89
 Beltrami, Silvia 105
 Benedetti, A. 63
 Ben-Gal, Y 71
 Benhameid, Osama 139
 Berdat, Pascal 168
 Berdat, Pascal A. 149
 Berger, F. 151
 Berglin, Eva 115
 Bergmann, Heinz 225, 230
 Bernecker, O. 238
- Bernstein, Rick V. 50
 Bettex, D. 231
 Beyer, Michael 135
 Beyersdorf, Friedhelm192
 Biancardi, L. 63
 Bisleri, Gianluigi65, 143
 Blackstone, Eugene H.76
 Bleese, Niels 58, 216, 225, 230
 Blome, Markus 40
 Bobos, D. 148
 Bochenek, Andrzej 78, 144, 145
 Boden, B. 56
 Bofman, P. 190
 Bolno, Paul B. 101
 Bolotin, Gil 188
 Bonanomi, G. 214
 Bonanomi, Gianluca 116, 240
 Bonaros, N. 238, 239
 Bonatti, J. 238, 239
 Borker, Shirish 51, 132
 Bortone, A.S. 178
 Bouchot, O. 73
 Boutsianis, Evangelos209
 Brenot, R. 73
 Brofman, P. 104, 118
 Buchness, Michael 103
 Butty, Vincent 209
- C
- Calafiore, A.M. 122
 Carpenter, Jeffery P. 154
 Carrel, Thierry 149
 Carrel, Thierry P. 168
 Casalino, S. 63
 Casher, Jennifer 223
 Cattaneo, E. 39
 Cattin, Philippe 237
 Ceglarek, W. 179
 Cesana, Eugenio 105
 Challapalli, John 159
 Chang, Jen-Ping 199
 Chang, Woo-Ik 79, 140
 Chatzis, A 235
 Chatzis, A. 148
 Cheema, Faisal H. 212, 223
- Cheung, A. 162
 Cheung, Albert T. 41
 Chevtchik, O. 238
 Chiariello, M. 155
 Chitwood, R. 213
 Choi, In Seok 205, 206
 Choughule, Ajay 51, 132
 Cicirata, Federico 105
 Cisowski, Marek 78, 144, 145
 Clivio, Alberto 105
 Cohen, Gideon 93
 Cohen, H.A. 214
 Colletti, Nicholas J. 212
 Copeland, Jack 221
 Corso, Paul J. 47, 204
 Cosgrove III, Delos M.76
 Cotrufo, M. 178
 Crouch, John D. 91
 Cutaia, Valeria 114
- D
- Däbritz, S. 158, 180
 D'Agostino, D. 178
 Danne, Matthias225, 230
 Danou, F. 142
 Danzmay, M. 239
 Dave, H. 151, 236
 Dave, Hitendu 44, 45, 208, 209, 237
 David, M. 73
 De Cillis, E. 178
 de Luca, L. 178
 Deja, M. 134, 179
 Deja, Marek A. 226
 Demaria, Roland 67
 Demers, P. 161
 Demertzis, S. 161
 Dencker, Andreas 192
 Deneke, Th. 46, 117
 DeRose, Joseph 133
 Desai, Nimesh D. 93
 Dessoffy, R. 98
 Di Tommaso, L. 155
 Dialectto, G. 178
 Dietrich, M. 68
 Dion, Robert 195
 Djoshibaev, S. 210
 Doi, K. 98

Doi, Kazuyoshi	76	Galbraith, T.	213	Helmchen, Udo	230
Domaradzki, W.	179	Garcia, Mario	76	Herz, I.	60
Doss, M.	68	Gardner, Timothy J.	57	Hetzer, Roland	153
Doss, Mirko	69, 172	Garrido, Mauricio	223	Higuchi, Shinya	218
Drucker, S.	162	Garrido, Mauricio J.	212	Hilker, Michael	129
Drzewiecka-Gerber, Agnieszka	144, 145	Gelpi, G.	70	Hill, Peter C.	204
Drzewiecki, Janusz	78, 144	Gelpi, Guido	38	Hoffmann, Bettina	58
Dullum, Mercedes K.C.	47	Gemel, M.	179	Hollander, Theresa	107
		Georgi, C.	56	Hollingsworth, Karen W.	212
E		Giannopoulos, N	235	Holmes, Elena	101
Eckstein, Friedrich S.	168	Giannopoulos, N.	148	Hook, L.	161
Edvardsson, Nils	115	Giffhorn, H.	104, 118, 190	Hosoda, Yasuyuki	83
Eller, M.	56, 127	Giovannini, Uberto	67		
Endo, Munemoto	139	Gleason, Thomas G.	171	I	
Engbers, Frank	195	Gołba, Krzysztof S.	226	Iannelli, G.	155
Entwistle III, John W. C.	101	Goldman, Bernard S.	93	Ibi, I.	161
Ergenoglu, Mehmet	88, 110	Goldman, SM.	131	Iino, Y.	74
Etienne, Pierre Yves	82, 228	Gomez, MC.	73	Ikedada, Tadashi	217
F		Gorman, Robert C.	154, 171	Iliev, R.	124
Fairman, Ronald M.	154	Graubitz, K.	68	Immer, Franz F.	168
Ferdinand, FD.	131	Griffis, Jack C.	184	Inagaki, Eiichiro	207
Fisher, Carol A.	107, 219	Grosso, Michael	220	Innorta, A.	70
Folliguet, Thierry	86	Gruenenfelder, Juerg	237	Inoue, M.	98
Francischelli, David E.	224	Gruenenfelder, J.	236	Insler, Steven	188
Frankel, Timothy L.	47, 204	Gruenenfelder, Jurg	208, 209	Isgro, Frank	40, 186
Frapier, Jean-Marc	67	Guden, Mustafa	88, 110	Itoh, Manabu	211
Frauenfelder, Thomas	209	Guerra, F.	63	J	
Fremes, Stephen E.	93	Guida, Maximo	72	Jain, Arvind K.	47, 204
Friedrich, G.	238, 239	Guimarães, M.	104, 118, 190	Jaklik, Andrzej	144, 145
Froilkis, Ina	188	Gulielmos, V.	56, 94, 127, 181	Jasinski, M. J.	179
Fukamachi, K.	98	Gundry, Steven	164	Jasinski, M.J.	134
Fukamachi, Kiyotaka	76	Gupta, Dipin	107, 219	Jasiński, Marek	226
Fukui, Toshihiro	83	H		Jayakar, David	90, 92, 221
Fumero, R.	39	Haaverstad, Rune	95	Jayakar, DV	222
Furukawa, Satoshi	107, 219	Haider, Kh H.	106	Jazayeri, S.	73
G		Hake, Ulrich	129	Jeevanandam, V	222
Gadeva, S.	124	Halloway, D.	162	Jeevanandam, V.	90
Gakidis, Ioannis	196	HAMEDANCHI, Ali	152	Jeevanandam, Valluvan	92
		Hamman, Baron L.	54	Johansson, Birgitta	115
		Hammerschmidt, Robert	153	Jones, Janice	107, 219
		Hamner, Chad E.	224	Julian, J. Stephen	103
		Hartmann, N.	127	Jumanazarov, A.	210
		Hausen, B.	161	Jun, Tae Gook	141
		Hebeler, R.	213		
		Hebsgaard, K.P.	214		

- K
- Kachel, Erez 66
 Kadner, A. 151, 231
 Kadner, Alexander 44, 233
 Kalarus, Z. 55
 Kalarus, Zbigniew 112
 Kanda, Louis 47
 Kang, Chang Hyun 79, 128, 140
 Kao, Chiung-Lun 199, 200
 Kapatnakis, Emmanouil I. 47
 Kappert, U. 94, 127
 Karwande, Shreekanth 215
 Katariya, Kushagra 187
 Katayama, Yuji 211
 Kessler, Michael 89
 Khalikov, U. 210
 Khargi, K. 46, 117
 Khargi, Krishna 111
 Kherani, Aftab R. 212, 223
 Kiessling, Arndt-H. 40
 Kiessling, Arndt-H. 186
 Kim, Chong Whan 205, 206
 Kim, Ki-Bong 79, 128, 140
 Kim, Soo Cheol 205, 206
 Kim, Woong-Han 205, 206
 Kim, Y. 214
 Kipfer, Beat 168
 Kirvassilis, G. 148
 Klautz, Robert 195
 Klein, Peter 75, 173
 Klopp, Edward 103
 Knapik, P. 55
 Knaut, M. 181
 Knollmann, Friedrich 153
 Kohmoto, Takushi 212
 Kolesov, Evgenii V. 201
 Kolowca, M. 134
 Kameda, Masashi 217
 Konertz, Wolfgang 89
 Kopcak, M. 98
 Kopcak, Michael 76
 Kotsis, V. 142
- Kouri, E. 142
 Kovac, M. 102
 Kowalik, V. 55
 Koyama, Tadaaki 217
 Kramer, A. 60
 Kramer, Amir 188
 Kruczak, Wojciech 78, 144, 145
 Kuinose, Masahiko 207
- L
- La Francesca, Saverio 170
 Lachat, M. 231, 236
 Lachat, Mario 233
 Laczkovics, A. 46, 117
 Lam, Nhung T. 92
 Laufer, G. 238, 239
 Law, PK. 106
 Lazar, Harold L. 160
 Lee, Dong Soo 128
 Lee, Hyun-Joo 79
 Lee, Young Tak 141
 Lefrak, Edward E. 203
 Lehmann, Claas 216
 Lemke, B. 46, 117
 Lemma, Massimo 38
 Lemma, M. 39, 70
 Lenarczyk, Radoslaw 112
 Leskosek, B. 236
 Lev-Ran, O. 71
 Lev-Ran, Oren 188
 Lichtenstein, S. 162
 Lim, Cheong 205, 206
 Ling, LH. 106
 Locker, C. 71
 Loewer, Christine 216
 Lombardi, Pierluca 187
 Lowery, Robert C. 47, 204
 Lu, JT. 106
 Lundell, Dwight C. 91
 Lutterman, Alison A. 224
- M
- Macha, Mahender 107, 219
 Mack, Michael J. 123
 Maehara, T. 74
 Magee, Mitchell J. 123
 Magovern, James 99
 Maia, F. 104, 190
- Mair, H. 158, 180
 Mair, Helmut 138
 Mallidi, Hari R. 93
 Mandke, Alka 132
 Mandke, Alka N. 51
 Mandke, Nitu 51, 132
 Manfredi, Jacopo 65, 143
 Mangia, F. 63
 Mangini, A. 39, 70
 Mangino, Domenico 114
 Mankad, Sunil 99
 Mannatrizio, G. 178
 Martens, S. 68
 Masroor, Saqib 187
 Matschke, K. 94
 Matza, Menahem 188
 McCarthy, P. 98
 McCarthy, Patrick M. 76
 McClurken, James B. 107, 219
 McGregor, Walter 99
 Meldrum, Patty 215
 Mihajlovic, B. 102
 Mihos, Peter 196
 Milani, R. 104, 118, 190
 Minato, Naoki 211
 Minematsu, Noritoshi 218
 Mishra, Y. 124
 Mittal, S. 124
 Miyazaki, Mizuo 217
 Mohr, R. 71
 Mohr, R. 60
 Molek, Armand 197, 198
 Monaco, A. 39
 Monaco, M. 155
 Morawski, Wl Odzimierz 145
 Morawski, Wlodzimierz 144
 Moretti, Roberto 114
 Morgan, Jeffrey A. 212, 223
 Moritz, A. 68
 Moser, G. William 171
 Moser, G. William 154
 Moura Jorge, J. 118
 Moutinho, J. 104, 118
 Mrozek, Roman 226
 Mueller, K-M. 46, 117
 Muneretto, Claudio 65, 143
 Muñoz, Gustavo 72

Murakami, Takashi	207	Park, Young Kwang	205, 206	Robbins, R.	161
N		Patel, Kirit N.	159	Roda, Jorge	194
Na, Chan-Young	205, 206	Pavlovic, Mladen	149	Rose, Eric A.	212
Nadalin, E.	118	Pawar, Rahul V.	160	Roysl, Johannes	192
Nadziakiewicz, P.	55	Paz, Josef	188	S	
Naka, Yoshifumi	212, 223	Paz, Y.	71	Sacco, L.	39
Nalladaru, Zubin	51	Paz, Y.	60	Sacco, Luigi	38
Navia, Jose L.	76	Pecora, Giuseppina	72	Sagbas, Ertan	88, 110
Neckel, Wulf	58	Peivandi, A.A.	129	Saggau, Werner	40, 186
Negri, Alberto	65, 143	Pelletier, Marc P.	93	Sahre, H.	56, 127
Nemeh, H.	98	Petrovic, Lj.	102	Saleh, M.	73
Nesher, Nahum	188	Pevni, D.	60	Salerno, Tomas	187
NEZAFATI, Mohammad Hassan	152	Pevni, Dmitry	188	Saltman, Adam	119
Ngyuen, Moui B.	159	Pfammatter, Jean-Pierre	149	Salzberg, S.	231
Nicolai, J.	127	Pfister, Albert J.	47	Salzberg, Sacha	233
Nifong, W.	213	Piacentino III, Valentino	107, 219	Samstad, Stein O.	95
Nikolov, D.	124	Piscione, F.	155	Samuel, Vicky	138
Nishimura, Kazunobu	217	Pochettino, Alberto	154	Samuels, Louis E.	101
Noah, Pierre Thierry	186	Polesel, Elvio	114	Sanisoglu, Ilhan	88, 110
Nollert, G.	180	Pontarolli, R.	104, 118	Sarris, G.	235
Nollert, Georg	138	Popov, M.	102	Sarris, G.	148
Novitzky, Dimitri	174, 175	Popovic, Z.	98	Saul, M.I.	214
O		Potaris, Konstantinos	196	Sayeed-Shah, Umer	160
Oberhoffer, Martin	59	Potic, Z.	102	Schachner, T.	238, 239
Oelert, Hellmut	129	Potter, D. Dean	224	Schaff, Hartzell V.	224
Ogburn, Nicholas	103	Poulikakos, Dimos	209	Schenk, S.	98
Oh, Sam Se	205, 206	Prapas, S.	142	Scherstén, Henrik	115
Okamoto, Yukiko	217	Prêtre, R.	151	Schinosa, Tupputi	178
Olszówka, P.	134, 179	Prêtre, René	44	Schmidli, Jürg	168
Olszówka, Piotr	226	Przybylski, R.	55	Schmöckel, M.	180
Ootaki, Y.	98	Przybylski, Roman	112	Schmöckel, S.	158
Ott, H.	238	Puszczewicz, Dariusz	112	Schneider, J.	94
Oz, Mehmet C.	212, 223	R		Schoellhorn, Joachim	192
P		Raab, Stephan	135	Schofer, Joachim	216
Pachinger, O.	239	Radovanovic, N.	102	Schütz, A.	180
Pacholewicz, Jerzy	112	Ramos, S.	148	Schwartzman, David	116, 240
Paeng, Jin Chul	128	Realyvasquez, F.	213	Scrofani, Roberto	38
Palma, Veronica A.	159	Redaelli, A.	39	Seiler, Christian	168
Panagiotopoulos, J.	142	Reesink, Koen	100	Shapira, Oz M.	160
Pantarolli, R.	190	Reichart, B.	158, 180	Sharkawy, A.	162
Paradiso, V.	178	Reichart, Bruno	138	Sharony, Ram	188
Park, Chun Soo	128	Renaud, C.	73	Sheishenov, J.	210
Park, Kay-Hyun	141	Rentz, Jeffrey	215	Shemin, Richard J.	160
Park, Pyo Won	141	Reuthebuch, O.	236	Shennib, Hani	133, 139
		Riess, Friedrich-Christian	58, 216, 230, 225	Sheraliev, A.	210
		Rikitake, Kazuhisa	211	Shimokawa, Tomoki	211
				Shin, H.	74
				Shofti, Rona	166
				Shreekanth Karwande	215

Shresta, Rajesh	145	Theissen, A.	68	Wahba, Alexander	95
Shuhaiber, Jeffrey H.	185, 232	Thomas, J.	98	Wan, Elaine	223
Sidiropoulos, A.	142	Thornton, Barbara A.	212	Warncke, K.	180
Silva, M.	104	Tio, Fermin O.	166	Wehberg, Kurt	103
Silveira, A.	190	Tjomsland, Ole	95	Weidinger, F.	238
Simon, P.	176	Toczek, Krzysztof	78	Weigang, Ernst	192
Simon-Kupilik, N.	176	Todd, James	103	Wertan, MA.	131
Singhal, Arun K.	107, 219	Toumpoulis, Ioannis	133	Whang, Song Wok	205, 206
Smith, Craig R.	212	Trace, CL.	131	Whisenant, Brian	215
Sobienski, Dennis	90	Trehan, N.	124	Whitman, G.R.	214
Soga, Yoshiharu	217	Trinkwitz, Micheal	58	Widenka, K.	134, 179
Song, David H.	64, 189	Tromsdal, Arve	95	Widenka, Kazimierz	226
Souza, J. A.	190	Trumble, Dennis	99	Wildermuth, Simon	209
Spampinato, N.	155	Trusz-Gluza, Maria	145	Williams, Mathew	223
Srivastava, Sudhir P.	159	Tschircov, A.	124	Wiseth, Rune	95
Srivastava, Vishwa P.	159	Tsoutsinos, A.	235	Wognsen, Gunnar	115
Stamou, Sotiris C.	47, 203, 204	Tugtekin, S. M.	181	Wolner, E.	176
Stendijk, Paul	195	Tulner, Sven	195	Woo, Y. Joseph	41, 57, 61
Stephenson, G.	222	Turina, M.	151, 231, 236	Wos, S.	179
Stocker, Reto	233	Turina, Marko	208, 209, 237	Wos, S.	134
Stratigi, P.	142	Turina, Marko I.	233	Woś, Stanisław	226
Stripling, Jan-Hendrik	225, 230	Turina, Marko I.	44		
Suda, Hisao	218			Y	
Suenaga, Etsuro	218, 229	U		Yamamoto, Shin	83
Sundt, Thoralf M.	224	Urbanski, Paul	169	Ye, Lei	106
Sung, Kiick	141	Uretzky, G.	71	Yozu, Ryohei	74
Sutter, Francis P.	131	Uretzky, G.	60		
Swarup, Ashok	132	Urmanbetov, K.	210	Z	
Swistel, Daniel	133			Zavaropoulos, P.	235
Szafranek, A.	179	V		Zaza, Antonio	105
Szczesniak, Slawomir	78	Valettas, Nicholas	61	Zeidner, Ann	223
Szekely, Gabor	237	van de Loo, Andreas	192	Zembala, M.	55
Szurlej, D.	134, 179	Vancura, Tobias	237	Zembala, Marian	112
T		vander Wall, Ernst	195	Zenati, M.A.	214
Tabry, Imad	52	Vanelli, Paolo	105	Zenati, Marco	116, 240
Tagarakis, G.	56	Varela, A.	190	Zhang, J.	162
Takagaki, Masami	207	Vega, Pablo Ruda	76	Zheng, Karl	223
Takai, Shinji	217	Ventikos, Yiannis	209	Zipfel, Burkhardt	153
Takanashi, Shuichiro	83	Venturini, Andrea	114	Zollinger, Peter	208
Takeda, Yuji	211	Vettath, Murali, P.	163	Zorc, M.	102
Tamirisa, Kris	159	Vicol, Calin	135	Zuend, Gregor	237
Tatou, E.	73	Vigilance, Deon W.	212, 223	Zund, G.	236
Tehrani, Hassan	187	Vitale, Nicola	95	Zünd, G.	231
Téot, Luc	67			Zund, Gregor	208, 209
Terrini, Alberto	114	W		Żurek, Paweł	226
				Zussa, Claudio	114

