

Clopidogrel-Related Refractory Bleeding after Coronary Artery Bypass Graft Surgery: A Rationale for the Use of Coagulation Factor Concentrates?

C. von Heymann,¹ H. Schoenfeld,¹ M. Sander,¹ S. Ziemer,² H. Grubitzsch,³ C. Spies¹

¹Department of Anaesthesiology and Intensive Care Medicine, ²Institute of Laboratory Medicine and Pathological Biochemistry, ³Department of Cardiovascular Surgery, Charité—University Medicine Berlin, Campus Charité Mitte, Berlin, Germany

ABSTRACT

Clopidogrel, an irreversible ADP-receptor antagonist, inhibits platelet aggregation mediated by reduced activation of glycoprotein receptor IIb/IIIa. Clopidogrel in combination with aspirin has been shown to be superior to aspirin alone for treating unstable angina, but clopidogrel recipients have shown increases in blood loss, transfusion requirements, and rate of reoperation after cardiac surgery. We describe a patient who had taken clopidogrel 75 mg daily until the day prior to coronary artery bypass graft surgery. Severe postoperative bleeding developed and was refractory to conventional hemostatic therapy consisting of 19 units of packed red blood cell concentrates, 16 of fresh frozen plasma, 8 of platelet apheresis concentrates plus high-dose treatment with aprotinin (500,000 kallikrein-inhibiting units/h) and administration of 0.3 µg/kg 1-deamino-8-D-arginine vasopressin (DDAVP). Two reoperations were performed, but surgical hemostasis was not achieved, so 100 µg/kg recombinant activated factor VII was applied to generate sufficient thrombin to stop the bleeding. This treatment approach reduced the bleeding. Then, to promote clot formation and firmness, 2 g of fibrinogen and 1250 IU of factor XIII were administered, and the bleeding finally stopped. No further transfusions were required, and the patient was discharged from the hospital on day 10 after the operation. This case suggests that in clopidogrel-related bleeding refractory to conventional hemostatic therapy, hemostasis may be achieved by a stepwise administration of coagulation factor concentrates.

INTRODUCTION

Clopidogrel combined with aspirin has been shown to decrease mortality in patients with unstable angina [Yusuf

2001], but this treatment has also resulted in a higher incidence of reoperation for bleeding [Yende 2001, Yusuf 2001]. Treatment with clopidogrel alone has been reported to increase bleeding complications and transfusion requirements after cardiac surgery [Ley 2001]. Furthermore, in noncardiac surgical patients severe bleeding complications have been reported [Schroeder 2001, Sare 2002]. Mortality in cardiac surgical patients with bleeding complications has been reported to be 2-fold higher than in nonbleeding patients [Moulton 1996], so an effective therapy for postoperative bleeding is required.

We report a patient who suffered clopidogrel-related bleeding after coronary artery bypass grafting. The bleeding was refractory to conventional and surgical hemostatic therapy, but it was successfully treated by a stepwise use of different coagulation factor concentrates.

CASE PRESENTATION

A 59-year-old man presented with an acute anterior myocardial infarction that was initially treated with the implantation of 2 stents in the left anterior descending artery (LAD). Despite combined treatment with acetylsalicylic acid (ASA) 100 mg and clopidogrel 75 mg daily (loading dose of 300 mg), the 6-week follow-up coronary angiography revealed multiple stenoses in front of and between the stents and in another native coronary artery. The patient was referred for coronary artery bypass grafting (CABG). ASA treatment was discontinued 5 days before and clopidogrel on the day before surgery.

CABG was performed with a left internal mammary artery to the LAD graft, and a saphenous vein graft to the ramus circumflexus.

The duration of the operation was 180 minutes with a cardiopulmonary bypass (CPB) time of 78 minutes and a cross-clamp time of 44 minutes. Heparin was administered prior to CPB at a dose of 25,000 IU, yielding an activated coagulation time (ACT) of 486 seconds. Another 10,000 IU of heparin was given during CPB. Heparin was reversed with 25,000 IU of protamin, resulting in an ACT of 118 seconds at the end of the operation.

The patient was admitted to the intensive care unit (ICU), and from the fourth postoperative hour he showed increased

Received August 16, 2004; received in revised form October 22, 2004; accepted November 1, 2004.

Address correspondence and reprint requests to: Christian von Heymann, MD, DEAA, Department of Anaesthesiology and Intensive Care Medicine, Charité—University Medicine Berlin, Campus Charité Mitte, Schumannstr 20-21, D-10117 Berlin, Germany; 0049-30-450-531012; fax: 0049-30-450-531911 (e-mail: christian.von_heyman@charite.de).

blood losses from the mediastinal and pleural drains (Figure). Coagulation lab values that were obtained prior to reoperation 1 and immediately before and after reoperation 2 showed a prolonged activated partial thromboplastin time (normal range, 26-40 seconds) and a slightly reduced fibrinogen level (normal range, 150-450 mg/dL) (Figure). Because transoesophageal echocardiography showed pericardial tamponade, and continued blood losses of 3200 mL occurred within the next 5 hours, the patient underwent reoperation. Up to that time, the patient had received 8 units of packed red blood cells (PRBC), 7 units of fresh-frozen plasma (FFP), 4 units of platelet apheresis concentrates (PC), 0.3 µg/kg desmopressin (1-deamino-8-D-arginine vasopressin [DDAVP]) and a continuous infusion of 500.000 kallikrein-inhibiting units [KIU]/h of aprotinin initiated by a bolus dose of 2000.000 KIU in total. During the procedure the patient received 2 PRBCs, 2 FFPs, and 1 PC, but no surgical source of bleeding was identified. After the first reoperation the patient showed further blood losses refractory to conventional hemostatic therapy (7 PRBCs, 5 FFPs, and 3 PCs and continued infusion of 500.000 KIU aprotinin/h). A second reoperation was performed that confirmed diffuse oozing of blood but did not find a surgical source of bleeding. Because surgical attempts to secure hemostasis and substitution of 2 PRBCs and 2 FFPs failed, 100 µg/kg recombinant activated factor VII (rFVIIa) was applied and did not completely stop the bleeding. In a second step, 2 g of fibrinogen and 1250 IU of factor XIII were administered, and this treatment stopped the diffuse bleeding. In the ICU the patient required no further transfusions, and he was discharged from the ICU on day 4 and from the hospital on day 10 after the operation in

good clinical condition without any clinical symptoms of acute thromboembolism.

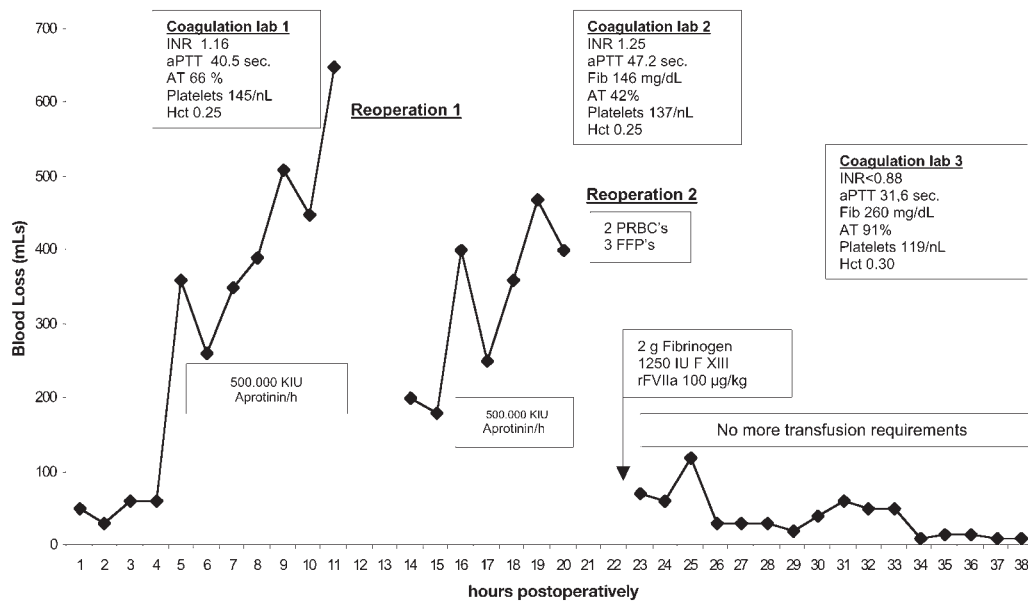
DISCUSSION

We report on a patient with post-CABG clopidogrel-related bleeding that was successfully treated with a stepwise substitution of rFVIIa and a fibrinogen and factor XIII concentrate.

According to the pharmacology of clopidogrel and its active metabolite SR 26334, the 6-week period of medication prior to operation should have resulted in irreversible inhibition of platelet aggregation mediated by fibrinogen-glycoprotein receptor IIb/IIIa interaction [Kam 2003]. Platelet aggregation recovers slowly after withdrawal of clopidogrel [Sharis 1998]. The active metabolite SR 26334 has a half-life of 8 hours [Kam 2003], so it has to be assumed that until complete clearance from plasma has occurred, substituted platelets may be inhibited by the circulating drug.

So far, no valid monitoring data of clopidogrel effects on platelet aggregation are available. In particular, the collagen-ADP activated closure time (ThrScr-ADP) of the platelet function analyzer assay (PFA-100; Dade Behring, Marburg, Germany) has not shown valid results in monitoring clopidogrel effects on platelet aggregation [Mueller 2003] nor has thrombelastography proven to be valid to measure the effect of clopidogrel on platelet aggregation.

In this patient severe bleeding after CABG surgery persisted despite massive substitution of FFP, PCs, high-dose aprotinin, and desmopressin (DDAVP). The second reoperation confirmed persistent oozing blood despite almost normal plasmatic coagulation parameters and platelet count (Figure),



Postoperative blood loss and coagulation parameters before and after recombinant activated factor VII (rFVIIa). Coagulation lab 1 indicates coagulation parameters before reoperation 1; Coagulation lab 2, coagulation parameters before reoperation 2; Coagulation lab 3, coagulation parameters after reoperation 2; INR, international normalized ratio of prothrombin time; aPTT, activated partial thromboplastin time; AT, antithrombin; PRBC, packed red blood cells; FFP, fresh frozen plasma; Platelets, platelet count; Hct, hematocrit; Fib, fibrinogen; F XIII, factor XIII; KIU, kallikrein inhibiting unit.

so coagulation factor concentrates were administered in a stepwise approach. The rationale for the administration of rFVIIa was to produce a thrombin burst at the site of bleeding [Monroe 1997]. The thrombin burst in turn activates platelets, because this mechanism is not inhibited by clopidogrel [Kam 2003]. This treatment did not completely stop the oozing blood, so 2 grams of fibrinogen and 1250 IU of factor XIII were applied in an attempt to provide sufficient substrate for clot formation at the site of bleeding (fibrinogen) and to stabilize the clots (factor XIII) [Schroeder 2001]. In this respect, it has been shown that factor XIII activity was reduced after cardiac surgery in patients with an increase in postoperative blood losses [Goedje 1998].

Even though this case report cannot answer the questions why recombinant factor VIIa was not completely successful and which coagulation factor concentrate finally stopped the bleeding, we suggest that refractory clopidogrel-related bleeding after cardiac surgery may benefit from a stepwise substitution of coagulation factor concentrates aiming at the generation of sufficient thrombin and promotion of clot formation and firmness. For clinical reasons coagulation factor concentrates should be applied stepwise and monitored closely to determine effective administration regimens and to evaluate the safety of this therapy.

REFERENCES

- Goedje O, Haushofer M, Lamm P, Reichart B. 1998. The effect of factor XIII on bleeding in coronary surgery. *Thorac Cardiovasc Surg* 46:263-7.
- Kam PCA, Nethery CM. 2003. The thienopyridine derivatives (platelet adenosine diphosphate receptor antagonists), pharmacology and clinical developments. *Anaesthesia* 58:28-35.
- Ley SJ. 2001. Quality care outcomes in cardiac surgery: the role of evidence-based practice. *AACN Clin Issues* 12:606-17.
- Monroe DM, Hoffmann MJ, Oliver JA, Roberts HR. 1997. Platelet activity of high-dose factor VIIa is independent of tissue factor. *Br J Haematol* 99:542-7.
- Moulton MJ, Creswell LL, Mackey ME, et al. 1996. Reexploration for bleeding is a risk factor adverse outcomes after cardiac operations. *J Thorac Cardiovasc Surg* 111:1037-46.
- Mueller T, Haltmayer M, Poelz W, Haidinger D. 2003. Monitoring aspirin 100 mg and clopidogrel 75 mg therapy with the PFA-100 device in patients with peripheral artery disease. *Vasc Endovasc Surg* 37(2):117-23.
- Sare GM, Lloyd FR, Stower MJ. 2002. Life-threatening haemorrhage after extracorporeal shockwave lithotripsy in a patient taking clopidogrel. *BJU International* 90:4:469.
- Schroeder V, Chatterjee T, Kohler HP. 2001. Influence of blood coagulation factor XIII and FXIII Val34Leu on plasma clot formation measured by thrombelastography. *Thromb Res* 104(6):467-74.
- Sharis PJ, Cannon CP, Loscalzo J. 1998. The antiplatelet effects of ticlopidine and clopidogrel. *Ann Intern Med* 129:394-405.
- Yende S, Wunderink RG. 2001. Effect of clopidogrel on bleeding after coronary artery bypass surgery. *Crit Care Med* 29(12):2271-5.
- Yusuf S, Zhao F, Mehta SR, et al. 2001. Clopidogrel in Unstable Angina to Prevent Recurrent Events Trial Investigators. Effects of clopidogrel in addition to aspirin in patients with acute coronary syndromes without ST-segment elevation. *N Engl J Med* 345(7):494-502.